

# Paroxysmal Kinesigenic Dyskinesia in Twins With Chromosome 16p11.2 Duplication Syndrome

Keisuke Ueda, MD, Marwan Shinawi, MD, and Toni S. Pearson, MD

*Neurol Genet* 2021;7:e549. doi:10.1212/NXG.000000000000549

Correspondence

Dr. Pearson

tpearson@wustl.edu

MORE ONLINE

▶ Video

Paroxysmal kinesigenic dyskinesia (PKD) (MIM# 128200) is a movement disorder characterized by brief episodes of involuntary movements consisting of dystonia, chorea, or myoclonus, usually triggered by sudden voluntary movements.<sup>1</sup> Pathogenic variants in *PRRT2* (MIM# 614386), located on chromosome 16p11.2, have been identified as the most common cause of PKD.<sup>2</sup> Most of the reported patients (approximately 80%) had the frameshift pathogenic variant c.649dupC (p. Arg217Profs\*8), which causes a premature stop codon. Other reported variants are nonsense, frameshift, or rarely missense that are predicted to cause a truncated protein, absence of protein product through nonsense-mediated mRNA decay, or nonfunctional protein.<sup>3</sup> Isolated PKD is typically associated with heterozygous intragenic variants in *PRRT2*. Symptomatic PKD has been reported in 6 patients with 16p11.2 microdeletion syndrome (MIM# 611913).<sup>4</sup> PKD is thus postulated to result from *PRRT2* haploinsufficiency. The reciprocal chromosome 16p11.2 duplication syndrome (MIM# 614671) is associated with autism, ADHD, developmental delay, intellectual disability, epilepsy, hypotonia, congenital anomalies, and microcephaly<sup>5,6</sup> but has not until now been associated with PKD.

## Case

Identical twin brothers presented to our clinic at age 5 years for the evaluation of episodic involuntary movements. They were born at 33 weeks' gestation by Cesarean section because of premature labor and breech presentation. Family history was significant for learning disability in both parents and mental health problems in the father. The pregnancy was complicated by prenatal diagnosis of talipes equinovarus deformity, which prompted amniocentesis and prenatal chromosomal microarray (CMA) that revealed a 674 kilobase interstitial microduplication at 16p11.2 (29,517,699–30,191,895) x3 (hg19).

Developmental delay became apparent at age 18 months, when they were unable to sit independently or speak single words. Both twins had impaired social interaction and impulsive behavior and were diagnosed with autistic spectrum disorder and started applied behavior analysis. Their foot anomaly was complicated by tendo-Achilles contractures and treated with serial casting and bilateral heel cord tenotomies. They subsequently walked independently at age 26 months.

Shortly after age 2 years, 1 twin developed 30- to 40-second episodes of dystonic posturing and athetosis of the upper and lower limbs (Video 1, [links.lww.com/NXG/A358](https://links.lww.com/NXG/A358)), triggered by sudden voluntary movements. At age 4 years, he developed generalized tonic-clonic seizures (GTCS), for which he started oxcarbazepine (OXC). At age 5 years, the episodes of involuntary movements occurred multiple times per day. Trihexyphenidyl partially controlled the symptoms.

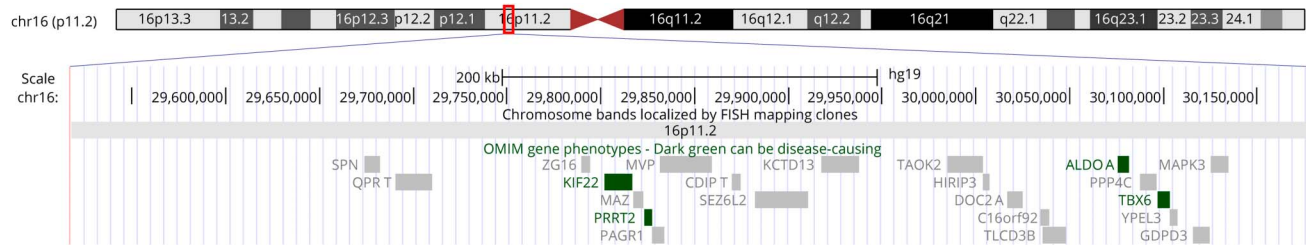
From the Department of Neurology (K.U., T.S.P.), and Division Genetics and Genomic Medicine (M.S.), Department of Pediatrics, Washington University School of Medicine, St. Louis, MO.

Go to [Neurology.org/NG](https://Neurology.org/NG) for full disclosures. Funding information is provided at the end of the article.

The Article Processing Charge was funded by the authors.

This is an open access article distributed under the terms of the Creative Commons Attribution-NonCommercial-NoDerivatives License 4.0 (CC BY-NC-ND), which permits downloading and sharing the work provided it is properly cited. The work cannot be changed in any way or used commercially without permission from the journal.

**Figure** Duplication Map of 16p11.2



Schematic representation of the duplicated 16p11.2 region using the University of California Santa Cruz Genome Browser ([genome.ucsc.edu/](http://genome.ucsc.edu/)). Top: a red rectangle indicates the duplicated region on the chromosome ideogram of 16p11.2. Bottom: a detailed map of the duplicated region, flanked by 2 blue lines, illustrates affected genomic coordinates and locations of Online Mendelian Inheritance in Man genes. Dark green boxes indicate disease-causing genes (e.g., *PRRT2*) for which the molecular basis of the disorder is known.

Investigations including brain and whole-spine MRI, urine organic acids, serum amino acids, and copper and ceruloplasmin levels were unremarkable. On our initial examination, he had mild generalized hypotonia without hyperreflexia or dysmorphic features. He was diagnosed with PKD. OXC was increased and trihexyphenidyl was discontinued. Ultimately, both the seizures and PKD episodes were controlled with OXC 32 mg/kg/d. Of note, a higher dose was needed to control the episodes of PKD than to control his seizures.

The other twin brother experienced GTCS at age 3 years, which subsided without any treatment, and experienced milder episodes of PKD that were controlled completely with OXC 13 mg/kg/d.

At age 8 years, both developed persistent urinary retention, and lumbar spine MRI revealed a tethered cord, which was surgically released with subsequent improvement in bladder and bowel function. Postnatal CMA revealed a 660 kilobase microduplication at 16p11.2 (29,517,698–30,177,240) x3 (hg19) (figure), which was almost identical to the result of the prenatal CMA. Targeted sequencing of *PRRT2* did not identify pathogenic variants.

## Discussion

We report monozygotic twins with chromosome 16p11.2 microduplication manifesting symptomatic PKD. Although 16p11.2 microduplication and deletion have many common clinical features,<sup>5</sup> cases of 16p11.2 microduplication have not been reported in association with PKD. Some of the twins' symptoms such as developmental delay, autistic spectrum disorder, hypotonia, and epilepsy commonly occur in 16p11.2 duplication carriers, but other clinical features of the syndrome such as skin lesions (e.g., café-au-lait spots and sacral dimples), cranial nerve abnormalities, hyper or hyporeflexia, tremor, tics, abnormal agility, abnormal brain MRI findings, or microcephaly were not observed in our patients.<sup>5</sup>

The *PRRT2*-related phenotypes such as PKD are caused by loss of function in 16p11.2 deletion and *PRRT2* sequence variants.<sup>4</sup> A mouse model of *PRRT2* deficiency demonstrated that loss of function in *PRRT2* deletion can be associated with abnormal synaptic transmission by altering soluble N-ethylmaleimide-sensitive factor attachment protein receptor (SNARE) protein function and behavioral episodes resembling PKD.<sup>7</sup>

The occurrence of PKD in our patients with 16p11.2 microduplication syndrome suggests that *PRRT2* haploinsufficiency is not the only possible mechanism underlying PKD, as has been previously hypothesized. Although we cannot exclude the possibility that a hypomorphic allele in the regulatory region of *PRRT2* exists as a second hit, our case suggests that dosage of *PRRT2* is important and that 16p11.2 microduplication, presumably associated with *PRRT2* gain of function may also cause PKD. The remarkably reduced penetrance for PKD in 16p11.2 rearrangements may relate to common polymorphisms on the remaining hemizygous allele, different genotypes elsewhere in the genome, or sex-dependent penetrance because all patients reported so far with PKD and these 16p11.2 alterations were men. Although *PRRT2* haploinsufficiency can be the mechanism for dosage sensitivity in 16p11.2 deletion, the pathogenicity in the reciprocal microduplication is not clear, but the surplus of *PRRT2* may interfere with the dosage balance required for the SNARE protein.

## Study Funding

No targeted funding reported.

## Disclosure

The authors report no financial conflicts of interest. Go to [Neurology.org/NG](http://Neurology.org/NG) for full disclosures.

## Publication History

Received by *Neurology: Genetics* August 17, 2020. Accepted in final form October 29, 2020.

## Appendix Authors

Name	Location	Contribution
<b>Keisuke Ueda, MD</b>	Washington University School of Medicine, St. Louis, MO	Acquisition of data, analysis and interpretation, completion of the first draft, and revision of the manuscript
<b>Marwan Shinawi, MD</b>	Washington University School of Medicine, St. Louis, MO	Acquisition of data, analysis and interpretation, critical revision of manuscript for intellectual content, and study supervision
<b>Toni S. Pearson, MD</b>	Washington University School of Medicine, St. Louis, MO	Acquisition of data, analysis and interpretation, critical revision of manuscript for intellectual content, and study supervision

## References

1. Bruno MK, Hallett M, Gwinn-Hardy K, et al. Clinical evaluation of idiopathic paroxysmal kinesigenic dyskinesia: new diagnostic criteria. *Neurology* 2004;63:2280–2287.
2. Wang JL, Cao L, Li XH, et al. Identification of PRRT2 as the causative gene of paroxysmal kinesigenic dyskinesias. *Brain* 2011;134:3493–3501.
3. Heron SE, Dibbens LM. Role of PRRT2 in common paroxysmal neurological disorders: a gene with remarkable pleiotropy. *J Med Genet* 2013;50:133–139.
4. Vlaskamp DRM, Callenbach PMC, Rump P, et al. PRRT2-related phenotypes in patients with a 16p11.2 deletion. *Eur J Med Genet* 2019;62:265–269.
5. Steinman KJ, Spence SJ, Ramocki MB, et al. 16p11.2 deletion and duplication: characterizing neurologic phenotypes in a large clinically ascertained cohort. *Am J Med Genet A* 2016;170:2943–2955.
6. Shinawi M, Liu P, Kang SH, et al. Recurrent reciprocal 16p11.2 rearrangements associated with global developmental delay, behavioural problems, dysmorphism, epilepsy, and abnormal head size. *J Med Genet* 2010;47:332–341.
7. Tan GH, Liu YY, Wang L, et al. PRRT2 deficiency induces paroxysmal kinesigenic dyskinesia by regulating synaptic transmission in cerebellum. *Cell Res* 2018;28:90–110.

# Neurology<sup>®</sup> Genetics

## Paroxysmal Kinesigenic Dyskinesia in Twins With Chromosome 16p11.2 Duplication Syndrome

Keisuke Ueda, Marwan Shinawi and Toni S. Pearson

*Neurol Genet* 2021;7;

DOI 10.1212/NXG.0000000000000549

**This information is current as of January 11, 2021**

<b>Updated Information &amp; Services</b>	including high resolution figures, can be found at: <a href="http://ng.neurology.org/content/7/1/e549.full.html">http://ng.neurology.org/content/7/1/e549.full.html</a>
<b>References</b>	This article cites 7 articles, 2 of which you can access for free at: <a href="http://ng.neurology.org/content/7/1/e549.full.html##ref-list-1">http://ng.neurology.org/content/7/1/e549.full.html##ref-list-1</a>
<b>Subspecialty Collections</b>	This article, along with others on similar topics, appears in the following collection(s): <b>All Genetics</b> <a href="http://ng.neurology.org/cgi/collection/all_genetics">http://ng.neurology.org/cgi/collection/all_genetics</a> <b>Chromosomes</b> <a href="http://ng.neurology.org/cgi/collection/chromosomes">http://ng.neurology.org/cgi/collection/chromosomes</a> <b>Motor Control</b> <a href="http://ng.neurology.org/cgi/collection/motor_control">http://ng.neurology.org/cgi/collection/motor_control</a>
<b>Permissions &amp; Licensing</b>	Information about reproducing this article in parts (figures, tables) or in its entirety can be found online at: <a href="http://ng.neurology.org/misc/about.xhtml#permissions">http://ng.neurology.org/misc/about.xhtml#permissions</a>
<b>Reprints</b>	Information about ordering reprints can be found online: <a href="http://ng.neurology.org/misc/addir.xhtml#reprintsus">http://ng.neurology.org/misc/addir.xhtml#reprintsus</a>

*Neurol Genet* is an official journal of the American Academy of Neurology. Published since April 2015, it is an open-access, online-only, continuous publication journal. Copyright © 2021 The Author(s). Published by Wolters Kluwer Health, Inc. on behalf of the American Academy of Neurology. All rights reserved. Online ISSN: 2376-7839.

