

PUS3 mutations are associated with intellectual disability, leukoencephalopathy, and nephropathy

Anderson Rodrigues Brandão de Paiva, MD, David S. Lynch, MD, PhD, Uirá Souto Melo, PhD, Leandro Tavares Lucato, MD, PhD, Fernando Freua, MD, Bruno Della Ripa de Assis, MD, Isabella Barcelos, MD, Clarice Listik, MD, Diego de Castro dos Santos, MD, Lúcia Inês Macedo-Souza, PhD, Henry Houlden, MD, PhD, and Fernando Kok, MD, PhD

Correspondence

Dr. de Paiva
arbrandaopaiva@gmail.com

Neurol Genet 2019;5:e306. doi:10.1212/NXG.000000000000306

Mutations in *PUS3*, which encodes a highly conserved enzyme responsible for post-transcriptional modification of tRNA, have been shown in a single family to be a cause of nonsyndromic intellectual disability (ID).¹ In this study, we used whole-exome sequencing (WES) to identify biallelic mutations in *PUS3* associated with syndromic ID with dysmorphic features, white matter disease (WMD), and renal abnormalities in a nonconsanguineous family from Brazil.

Clinical findings

We evaluated 2 sisters (figure, A) who had ID, renal abnormalities, diffuse WMD, and dysmorphic features. Their brother was similarly affected and died at age 22 years of complications of renal disease. The parents were nonconsanguineous from Northeast Brazil and Southern Italy. We obtained approval from the institutional ethics committee and written informed consent from family members.

The first patient (P1; III-3; figure, A) was noted to have global developmental delay after age 1 year. As a child, she could understand short sentences, but expressive language was limited to monosyllables. She was diagnosed with profound ID but was independent in basic activities of daily living (ADLs). She had 2 focal dyscognitive seizures with secondary generalization, at age 18 and 23 years, responsive to carbamazepine. At age 37 years, asymptomatic proteinuria and reduced creatinine clearance were detected. At 44 years, she developed psychosis, with prominent auditory and visual hallucinations and episodes of aggression. Physical examination revealed her to be on the 10th centile for height, weight, and head circumference and to have genu valgum. In addition, neurologic examination revealed dysarthria, pseudobulbar affect, with impaired gait and balance.

The second patient (P2; III-6; figure, A) also presented with short stature, neurodevelopmental delay, and dysmorphic features. She was diagnosed with acute nephritis at age 6 months and coeliac disease at age 5 years. She also developed generalized phenobarbital responsive seizures. She was able to walk and could complete ADLs with assistance. At age 20 years, she developed nephrotic syndrome due to focal segmental glomerulosclerosis (FSGS) with mesangial granular deposits and positive IgM and C3 immunofluorescence. She did not respond to steroids and developed end-stage renal failure requiring hemodialysis. Physical examination revealed that she was on the 3rd centile for height, weight, and head circumference and to have gray

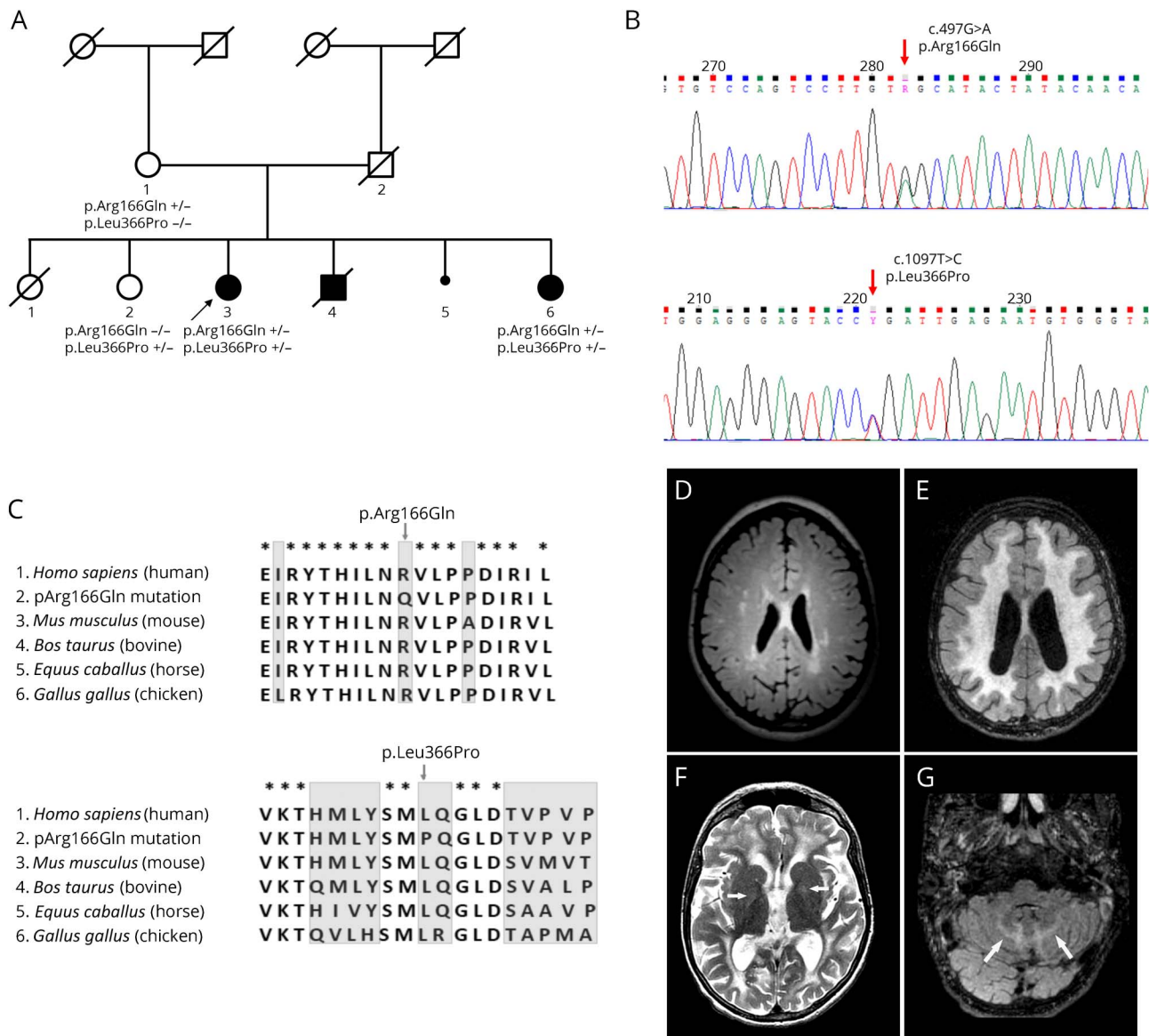
From the Neurogenetics Unit (A.R.B.d.P., F.F., B.D.R.d.A., I.B., C.L., D.d.C.d.S., F.K.), Neurology Department, Hospital das Clínicas da Universidade de São Paulo, Brazil; Department of Molecular Neuroscience (D.S.L., H.H.), UCL Institute of Neurology, London, UK; Leonard Wolfson Experimental Neurology Centre (D.S.L., H.H.), UCL Institute of Neurology, London, UK; Human Genome and Stem Cell Research Center (U.S.M., L.I.M.-S., F.K.), Department of Genetics and Evolutionary Biology, Instituto de Biociências, Universidade de São Paulo, Brazil; and Neuroradiology Section (L.T.L.), Hospital das Clínicas da Universidade de São Paulo, Brazil.

Funding information and disclosures are provided at the end of the article. Full disclosure form information provided by the authors is available with the full text of this article at Neurology.org/NG.

The Article Processing charge was funded by the authors.

This is an open access article distributed under the terms of the Creative Commons Attribution-NonCommercial-NoDerivatives License 4.0 (CC BY-NC-ND), which permits downloading and sharing the work provided it is properly cited. The work cannot be changed in any way or used commercially without permission from the journal.

Figure Genetic and radiologic findings



(A) Family pedigree: 2 affected individuals were compound heterozygotes for p.Arg166Gln and p.Leu366Pro *PUS3* mutations, whereas their healthy mother and sister were heterozygotes for only 1 of the mutations. (B) Sanger sequencing electropherograms showing both c.497G>A (p.Arg166Gln) and c.1097T>C (p.Leu366Pro) *PUS3* mutations. (C) Vertebrate protein sequencing alignment showing conserved amino acid sites for both *PUS3* mutations. (D) Scattered FLAIR hyperintensities in the cerebral white matter in P1. (E) Symmetric diffuse FLAIR hyperintensity in the cerebral white matter in P2. (F) Axial T2-weighted image discloses not only the white matter changes in P2 but also mild T2 hyperintensity in the globus pallidus bilaterally (arrows). One can notice also in P2 symmetric FLAIR hyperintensities in the cerebellar white matter (arrows in G), together with signs of brain parenchyma volume loss (E–G).

sclera, genu valgum, pseudobulbar affect, and dysarthria. She died at age 40 years of complications of community-acquired pneumonia.

Neuroimaging findings

MRI identified white matter abnormalities in both patients. In P1, there were scattered T2/fluid-attenuated inversion recovery (FLAIR) hyperintensities in the cerebral white matter, more prominent in periventricular zones (figure, D). In P2, there was symmetric diffuse T2/FLAIR hyperintensity in the cerebral and cerebellar white matter with extension to the subcortical areas,

mild T2 hyperintensity in the globus pallidus bilaterally, and signs of brain parenchymal volume loss (figure, E–G). There was no gadolinium enhancement or areas of restricted diffusion.

Genetic findings

We performed WES on both patients and filtered the data for a presumed autosomal recessive inheritance pattern. There were no regions of homozygosity and no shared rare homozygous variants. However, when filtered for damaging, rare compound heterozygous mutations, we identified biallelic mutations only in *PUS3* (p.Arg166Gln;p.Leu366Pro)

(figure, B). Both are very rare and highly conserved residues among vertebrates. We confirmed the mutations by Sanger sequencing and demonstrated that they were inherited in trans.

Discussion

PUS3 codes for pseudouridylylase synthase, a highly conserved enzyme responsible for posttranscriptional modification of tRNA,² which is critical for its structure, function, and stability. Most of these modifications have been recently recognized in a growing number of human genes leading to ID–*FTSJ1*, *TRMT1*, *NSUN2*, *WDR4*, *ADAT3*, and *PUS3*.³

The original report of *PUS3*-related disorder describes a family with 3 affected individuals (age: 3–15 years) from Saudi Arabia with severe ID, multifocal white matter changes, and in a single patient, epilepsy. No nephropathy was reported. WES detected a homozygous truncating mutation (p.Arg435Ter), predicting to lead to a loss of function. In our patients, affected individuals have a milder intellectual compromise and developed proteinuria/nephrotic syndrome after age 20 years. In addition, the white matter abnormalities were more extensive in our patients.

Of interest, a well-known mechanism of WMD is disruption of protein translation as is seen in mutations in mitochondrial aspartate (*DARS2*) or glutamate (*EARS2*) transfer-RNA synthase. It is also noteworthy that leukoencephalopathies usually cause progressive neurologic deterioration and not static encephalopathy with ID, as occurred in our patients.

The late-onset renal involvement observed in our patients expands the phenotype of *PUS3*-related disorder. Steroid-resistant FSGS has been rarely associated with mutations in mitochondrial tRNA in patients with other features typical of mitochondrial dysfunction.^{4–7} Recently, tubulopathy was reported in deficiency of tRNA N⁶-adenosine threonylcarbamoyltransferase, an enzyme involved in posttranscriptional tRNA modification.

This study expands the known phenotypic and allelic spectrum of *PUS3*-related disorder. In addition, it provides further evidence of the relevance of posttranscriptional modification of tRNA in neurologic diseases. Given these additional findings, we believe the phenotypic spectrum of *PUS3* mutations to be wider than the initial report.

Acknowledgment

The authors thank the patients and their family for participating in this study.

Study funding

No targeted funding reported.

Disclosure

A.R.B. de Paiva, D.S. Lynch, and U.S. Melo report no disclosures. L.T. Lucato has received speaker honoraria from Bracco Imaging

Appendix 1. Author contributions

Name	Location	Role	Contribution
Anderson Rodrigues Brandão de Paiva, MD	Neurogenetics Unit, Neurology Department, Hospital das Clínicas da Universidade de São Paulo, São Paulo, Brazil	Author	Study concept and design, acquisition of data, and writing the manuscript.
David S. Lynch, MD, PhD	UCL Institute of Neurology, London, United Kingdom	Author	Study concept and design, acquisition of data, and writing the manuscript.
Uirá Souto Melo, PhD	Human Genome and Stem Cell Research Center, Department of Genetics and Evolutionary Biology, Instituto de Biociências, Universidade de São Paulo, São Paulo, Brazil	Author	Acquisition of data and critical revision of the manuscript.
Leandro Tavares Lucato, MD, PhD	Neuroradiology Section, Hospital das Clínicas da Universidade de São Paulo, São Paulo, Brazil	Author	Acquisition of data and critical revision of the manuscript.
Fernando Freua, MD	Neurogenetics Unit, Neurology Department, Hospital das Clínicas da Universidade de São Paulo, São Paulo, Brazil	Author	Acquisition of data and critical revision of the manuscript.
Bruno Della Ripa de Assis, MD	Neurogenetics Unit, Neurology Department, Hospital das Clínicas da Universidade de São Paulo, São Paulo, Brazil	Author	Acquisition of data and critical revision of the manuscript.
Isabella Barcelos, MD	Neurogenetics Unit, Neurology Department, Hospital das Clínicas da Universidade de São Paulo, São Paulo, Brazil	Author	Acquisition of data and critical revision of the manuscript.
Clarice Listik, MD	Neurogenetics Unit, Neurology Department, Hospital das Clínicas da Universidade de São Paulo, São Paulo, Brazil	Author	Acquisition of data and critical revision of the manuscript.
Diego de Castro dos Santos, MD	Neurogenetics Unit, Neurology Department, Hospital das Clínicas da Universidade de São Paulo, São Paulo, Brazil	Author	Acquisition of data and critical revision of the manuscript.
Lúcia Inês Macedo-Souza, PhD	Human Genome and Stem Cell Research Center, Department of Genetics and Evolutionary Biology, Instituto de Biociências, Universidade de São Paulo, São Paulo, Brazil	Author	Acquisition of data and critical revision of the manuscript.
Henry Houlden, MD, PhD	UCL Institute of Neurology, London, United Kingdom	Author	Critical revision of the manuscript
Fernando Kok, MD, PhD	Neurogenetics Unit, Neurology Department, Hospital das Clínicas da Universidade de São Paulo, São Paulo, Brazil	Author	Critical revision of the manuscript

do Brasil and has served on the editorial board of *Arquivos de Neuro-Psiquiatria*. F. Freua, B.D.R. de Assis, I. Barcelos, C. Listik, D. Castro Santos, and L.I. Macedo-Souza report no disclosures. H. Houlden has received governmental and/or foundation/society support from the Medical Research Council (MRC) UK, the BRT, the MDA USA, Muscular Dystrophy UK, Ataxia UK, Muscular Dystrophy UK, Rosetrees Trust, the Wellcome Trust, and the National Institute for Health Research (NIHR) UCL/UCLH BRC. F. Kok has served on the editorial board of *Arquivos de Neuro-Psiquiatria*; holds a patent for methylmalonic acid determination by tandem mass spectrometry using stable isotope; is employed as Medical Director for Mendelics Genomic Analysis; has acted as a speaker for Actelion Pharmaceuticals at the NPC symposia and for BioMarin Pharmaceuticals at the CLN2 symposia; and has been a shareholder of Mendelics Genomic Analysis. Full disclosure form information provided by the authors is available with the full text of this article at Neurology.org/NG.

Publication history

Received by *Neurology: Genetics* August 13, 2018. Accepted in final form November 8, 2018.

References

1. Shaheen R, Han L, Faqeih E, et al. A homozygous truncating mutation in PUS3 expands the role of tRNA modification in normal cognition. *Hum Genet* 2016;135:707–713.
2. Hur S, Stroud RM. How U38, 39, and 40 of many tRNAs become the targets for pseudouridylation by TruA. *Mol Cell* 2007;26:189–203.
3. Torres AG, Batlle E, Ribas de Pouplana L. Role of tRNA modifications in human diseases. *Trends Mol Med* 2014;20:306–314.
4. Dinour D, Mini S, Polak-Charcon S, Lotan D, Holtzman EJ. Progressive nephropathy associated with mitochondrial tRNA gene mutation. *Clin Nephrol* 2004;62:149–154.
5. Scaglia F1, Vogel H, Hawkins EP, Vladutiu GD, Liu LL, Wong LJ. Novel homoplasmic mutation in the mitochondrial tRNA^{Tyr} gene associated with atypical mitochondrial cytopathy presenting with focal segmental glomerulosclerosis. *Am J Med Genet A* 2003;123A:172–178.
6. Guéry B, Choukroun G, Noël LH, et al. The spectrum of systemic involvement in adults presenting with renal lesion and mitochondrial tRNA(Leu) gene mutation. *J Am Soc Nephrol* 2003;14:2099–2108.
7. Hotta O, Inoue CN, Miyabayashi S, Furuta T, Takeuchi A, Taguma Y. Clinical and pathologic features of focal segmental glomerulosclerosis with mitochondrial tRNA^{Leu(UUR)} gene mutation. *Kidney Int* 2001;59:1236–1243.

Neurology[®] Genetics

***PUS3* mutations are associated with intellectual disability, leukoencephalopathy, and nephropathy**

Anderson Rodrigues Brandão de Paiva, David S. Lynch, Uirá Souto Melo, et al.

Neurol Genet 2019;5;

DOI 10.1212/NXG.0000000000000306

This information is current as of January 16, 2019

Updated Information & Services	including high resolution figures, can be found at: http://ng.neurology.org/content/5/1/e306.full.html
References	This article cites 7 articles, 1 of which you can access for free at: http://ng.neurology.org/content/5/1/e306.full.html##ref-list-1
Subspecialty Collections	This article, along with others on similar topics, appears in the following collection(s): All Genetics http://ng.neurology.org/cgi/collection/all_genetics Leukodystrophies http://ng.neurology.org/cgi/collection/leukodystrophies Mental retardation http://ng.neurology.org/cgi/collection/mental_retardation
Permissions & Licensing	Information about reproducing this article in parts (figures, tables) or in its entirety can be found online at: http://ng.neurology.org/misc/about.xhtml#permissions
Reprints	Information about ordering reprints can be found online: http://ng.neurology.org/misc/addir.xhtml#reprintsus

Neurol Genet is an official journal of the American Academy of Neurology. Published since April 2015, it is an open-access, online-only, continuous publication journal. Copyright © 2019 The Author(s). Published by Wolters Kluwer Health, Inc. on behalf of the American Academy of Neurology. All rights reserved. Online ISSN: 2376-7839.

