

Genomic deletions upstream of lamin B1 lead to atypical autosomal dominant leukodystrophy

Bruce Nmezi, BS,* Elisa Giorgio, PhD,* Raili Raininko, MD, PhD, Anna Lehman, MD, Malte Spielmann, MD, Mary Kay Koenig, MD, Rahmat Adejumo, MBBS, Melissa Knight, BS, Ralitza Gavriloova, MD, Murad Alturkustani, MD, Manas Sharma, MD, Robert Hammond, MD, William A. Gahl, MD, PhD, Camilo Toro, MD,# Alfredo Brusco, PhD,# and Quasar S. Padiath, MBBS, PhD#

Correspondence
Dr. Padiath
qpadiath@pitt.edu

Neurol Genet 2019;5:e305. doi:10.1212/NXG.0000000000000305

Abstract

Objective

Clinical, radiologic, and molecular analysis of patients with genomic deletions upstream of the *LMNB1* gene.

Methods

Detailed neurologic, MRI examinations, custom array comparative genomic hybridization (aCGH) analysis, and expression analysis were performed in patients at different clinical centers. All procedures were approved by institutional review boards of the respective institutions.

Results

Five patients from 3 independent families presented at ages ranging from 32 to 52 years with neurologic symptoms that included progressive hypophonia, upper and lower limb weakness and spasticity, and cerebellar dysfunction and MRIs characterized by widespread white matter alterations. Patients had unique nonrecurrent deletions upstream of the *LMNB1*, varying in size from 250 kb to 670 kb. Deletion junctions were embedded in repetitive elements. Expression analysis revealed increased *LMNB1* expression in patient cells.

Conclusions

Our findings confirmed the association between *LMNB1* upstream deletions and leukodystrophy previously reported in a single family, expanding the phenotypic and molecular description of this condition. Although clinical and radiologic features overlapped with those of autosomal dominant leukodystrophy because of *LMNB1* duplications, patients with deletions upstream of *LMNB1* had an earlier age at symptom onset, lacked early dysautonomia, and appeared to have lesser involvement of the cerebellum and sparing of the spinal cord diameter on MRI. aCGH analysis defined a smaller minimal critical region required for disease causation and revealed that deletions occur at repetitive DNA genomic elements. Search for *LMNB1* structural variants (duplications and upstream deletions) should be an integral part of the investigation of patients with autosomal dominant adult-onset leukodystrophy.

*Denotes equal contribution.

#Denotes senior authors.

From the Department of Human Genetics (B.N., Q.S.P.), Graduate School of Public Health, University of Pittsburgh; Department of Medical Sciences (E.G., A.B.), University of Torino, Italy; Department of Radiology (R.R.), Uppsala University, Sweden; Department of Medical Genetics (A.L.), British Columbia Children's Hospital, Vancouver, Canada; Department of Genome Sciences (M. Spielmann), University of Washington, Seattle; Department of Pediatrics (M.K.K., R.A., M.K.), McGovern Medical School, University of Texas, Houston; Departments of Clinical Genomics and Neurology (R.G.), Mayo Clinic, Rochester, MN; Department of Pathology (M.A.), King Abdulaziz University, Jeddah, Saudi Arabia; Department of Medical Imaging (M. Sharma), Western University, London, Canada; Departments of Pathology and Clinical Neurological Sciences (R.H.), Western University and London Health Sciences Centre, Canada; Office of the Clinical Director (W.A.G., C.T.), NHGRI; and NIH Undiagnosed Diseases Program (W.A.G., C.T.), Office of the Director, NIH, Bethesda, MD.

Funding information and disclosures are provided at the end of the article. Full disclosure form information provided by the authors is available with the full text of this article at Neurology.org/NG.

The Article Processing Charge was funded by NIH.

This is an open access article distributed under the terms of the Creative Commons Attribution-NonCommercial-NoDerivatives License 4.0 (CC BY-NC-ND), which permits downloading and sharing the work provided it is properly cited. The work cannot be changed in any way or used commercially without permission from the journal.

Glossary

aCGH = array comparative genomic hybridization; **ADLD** = autosomal dominant leukodystrophy; **LINE** = long interspersed nucleotide element; **SI** = signal intensity; **TAD** = topologically associated domain.

Autosomal dominant leukodystrophy (ADLD, OMIM #169500) is a fatal, progressive neurologic disorder that presents in the 4th to 6th decade of life and primarily affects CNS myelin.^{1,2} Patients present with progressive autonomic dysfunction, followed by disturbance of motor control as a result of cerebellar deficits and spasticity; death occurs 10–20 years after the onset of symptoms.^{2–4}

We have previously shown that ADLD is caused by a duplication of the lamin B1 gene (*LMNB1*, chr5q23.2), resulting in increased *LMNB1* protein expression.^{4,5} Although only *LMNB1* duplications have been definitively shown to cause ADLD, we recently identified a genomic deletion upstream of the *LMNB1* gene in a single large pedigree (ADLD-1-TO) that resulted in a phenotype similar to ADLD caused by *LMNB1* duplications.⁶ As the mutation was identified in only a single family, it was difficult to unequivocally confirm the link between the *LMNB1*-associated deletions and the leukodystrophy phenotype.

In this report, we present the analysis of 3 novel families with genomic deletions of varying sizes upstream of the *LMNB1*. The identification of a larger cohort of patients allows us to confirm the association between *LMNB1* upstream deletions and disease, define a broader phenotypic spectrum associated with the mutation, and acquire mechanistic insights into the cause of this genomic rearrangement.

Methods

Five patients, belonging to 3 independent families, were examined because of adult-onset neurologic dysfunction. Array comparative genomic hybridization (aCGH) using a custom array, bioinformatics, and expression analysis was performed as described earlier.^{4,6} Histopathologic analysis and brief clinical and MRI findings from patient DEL2-1 have been described previously.⁷

Standard protocol approvals, registrations, and patient consents

Clinical and radiologic evaluations took place under the guidelines of the respective institutional review boards, and all patients provided written informed consent.

Data availability statement

All data used in this study are included in this report or accompanying supplementary information.

Results

Clinical characteristics of the 5 patients are described in table 1 and e-supplementary clinical information (links.

lww.com/NXG/A135). The age at onset of neurologic symptoms ranged from 32 to 52 years. Presenting symptoms included dysarthria and hypophonia (4/5), poor dexterity (4/5), imbalance (3/5), weakness of the extremities, including asymmetrical weakness (3/5), tremor (2/5), and painful leg spasms (1). Of note, early involvement of the autonomic nervous system was notable in only 1 patient with orthostatic intolerance and urinary urgency. In 2 patients, urinary urgency and incontinence were late features of the disorder, occurring only after development of severe lower limb spasticity. Two patients indicated significant propensity for worsening of symptoms in relation to elevated environmental heat and humidity.

Four patients underwent brain MRI (figure 1); all had a corticospinal tract involvement extending from the upper frontal lobes to the cerebral peduncles. Three patients (DEL1-1, DEL2-1, and DEL3-1) had extensive symmetrical white matter hyperintensities in all cerebral lobes with a less affected periventricular rim on T2-weighted spin-echo images. Patient DEL3-2 was unique, as she did not exhibit extensive lobar involvement compared with other patients. Of interest, the central parts of the pathologic areas in this patient showed a low signal intensity (SI) on T2-weighted fluid-attenuated inversion recovery images indicating high fluid content. The upper cervical spinal cord was seen in the sagittal brain images. The anteroposterior diameters at C II were below the normal range in all patients. MRI of the cervical and upper thoracic spine, obtained in DEL3-1 and DEL2-1, did not reveal atrophy at the lower levels, nor obvious SI alterations.

Patients were negative for mutations in known disease-causing genes including *LMNB1* duplications (e-supplementary clinical information, links.lww.com/NXG/A135). Subsequent analysis using a custom aCGH assay allowed us to identify and map deletions upstream of the *LMNB1* gene (figure 2). Deletions were unique to each family and ranged from ~670 kb to ~250 kb extending to within 88 kb–4.8 kb upstream of the *LMNB1* start codon, respectively (table e-1). Analysis of the deletion boundaries (including those from the previously published ADLD-1-TO deletion) revealed that 3 of the 4 boundaries were in *Alu* repeats. The telomeric end of the DEL3 deletion was situated in a long interspersed nucleotide element (LINE) repeat element. A careful examination of the centromeric end of this deletion revealed a 20-bp region that had a high degree of homology to LINE elements. Thus, all the deletion boundaries appear to be embedded in some type of

Table 1 Clinical data

Patient	DEL1-1	DEL2-1	DEL3-1	DEL3-2	DEL3-3
Sex	Male	Male	Female	Female	Male
Age at symptom onset (y)	34	52	37	34	32
Ethnicity	East Asian	Northern European	Northern European/ Native American	Northern European/ Native American	Northern European/ Native American
Living status (age in years)	Alive (40)	Deceased (59)	Alive (42)	Deceased (36)	Deceased (50)
Presenting complaint at disease onset	Right hand tremor and voice difficulties	Leg cramps and slowly progressive spasticity	Hypophonia, dysarthria, and hand incoordination	Soft/slurred speech and hand incoordination	Decreased dexterity of upper limb weakness and dysarthria
Affect	Normal	Chronic anxiety	Depressed mood	Normal	Pseudobulbar affect
Oral motor control and articulation	Soft “breathy” and halting voice and dysphagia	Speech was normal	Muffled voice, unilateral facial weakness, and drooling	Speech apraxia and dysphagia	Dysarthria
Eye and extraocular movement examination	Normal	Fine end-point nystagmus on lateral gaze. Interrupted saccades, in vertical and horizontal planes	Normal dilated examination, Saccadic intrusion	Optic disk pallor, limited up-gaze and saccadic intrusion	Normal
Motor examination	Head and hand tremor (asymmetrical), incoordination and spastic and ataxic gait, and weakness of lower extremities	Tremor of lower extremities, spasticity, and cerebellar deficits	Asymmetrical spastic weakness of upper and lower extremities	Asymmetrical (left > right) spastic weakness of upper and lower extremities	Decreased dexterity upper limb spasticity and asymmetrical weakness of both upper and lower limbs (right > left)
DTRs/plantar responses	Brisk with clonus/extensor	Spastic in all limbs with lower limb clonus; positive Hoffman response	Lower extremity clonus/extensor	Brisk	Brisk/extensor
Sensory examination	Normal	Normal	Normal	Normal	Normal
Autonomic nervous system	Early orthostatic intolerance and urinary urgency	Late urinary urgency and incontinence	Normal by history and laboratory testing ^a	Normal by history	Late urinary urgency
EMG/NCV	NA	Normal	Normal	L peroneal entrapment neuropathy	NA
Family history and inheritance patterns	Negative	Positive/autosomal dominant	Positive/autosomal dominant	Positive/autosomal dominant	Positive/autosomal dominant
Comorbidities	Migraines, gout, and dyslipidemia	Hypertension, GERD, and DJD	None	None	None
Other	Neurologic deficits worsened with respiratory infection	Snout reflex	Neurologic deficits reported to be worsened by environmental heat	Dyspnea likely from neuromuscular weakness; L leg pain likely from peroneal neuropathy	Neurologic deficits reported to be worsened by environmental heat

Abbreviations: DJD = degenerative joint disease; DTR = deep tendon reflex; GERD = gastroesophageal reflux disease; NA = not available; NCV = nerve conduction velocity.

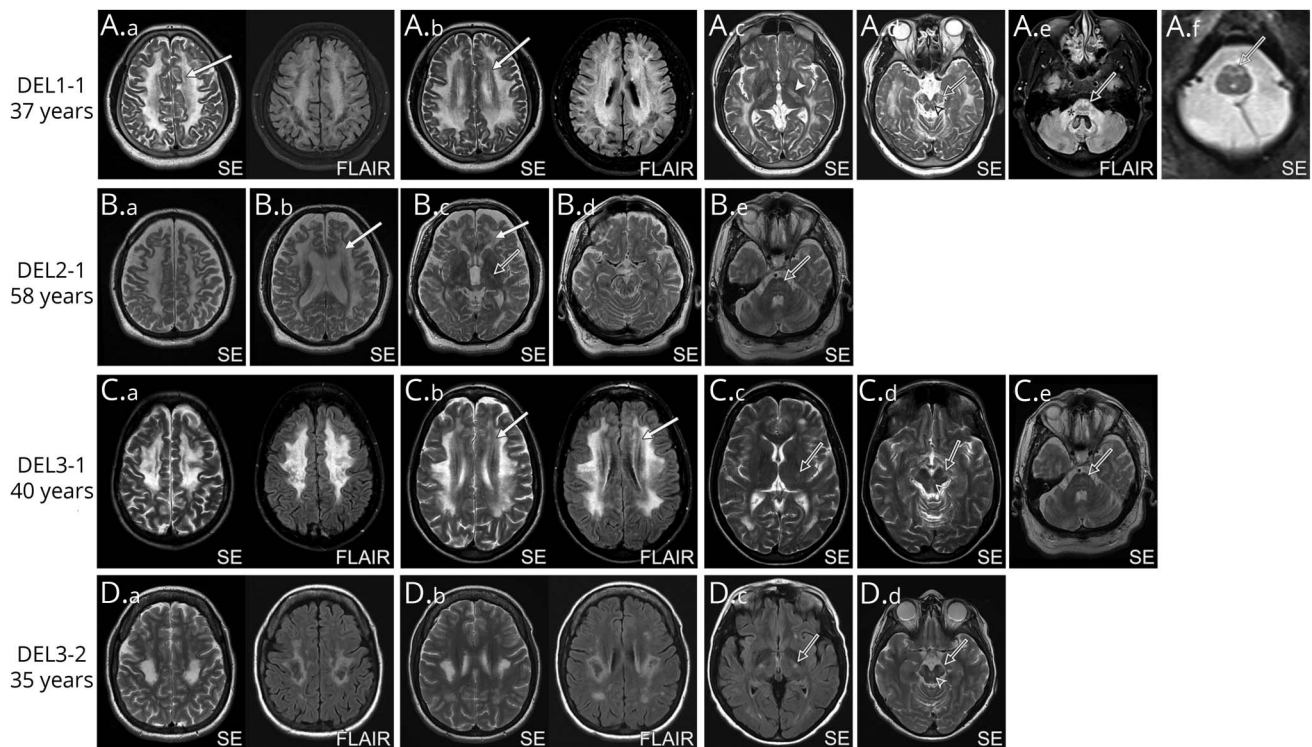
^a Included R-R variability, Tilt-table test, Valsalva maneuver, and sudomotor axon reflex test.

repetitive DNA element. Expression analysis revealed increased levels *LMNB1* mRNA in cells from one of the patients (DEL1-1), consistent with the report on the ADLD-TO family (table e-2).⁶

Discussion

Patients with deletions upstream of the *LMNB1* gene had clinical and radiologic signs that exhibited both unique findings

Figure 1 Brain MRI features in patients with deletions upstream of *LMNB1*



All images are T2-weighted. (A) Patient DEL1-1 had the most extensive changes. Very high SI in the frontal, parietal, occipital, and temporal white matter and even juxtacortical areas were pathologic (A.a–A.d). The periventricular area was less affected on SE images (A.a, A.b, arrows) but exhibited a very high signal on FLAIR images. The entire posterior limb of the internal capsule was pathologic (A.c, arrowhead). The corticospinal tract (open arrow) had a high SI also in the cerebral crura (A.d), pons (A.e), and pyramids of the medulla oblongata (A.f). High SI in the decussation of the superior cerebellar peduncles (A.d, open arrowhead) and in the middle cerebellar peduncles was observed (A.e, star). The splenium was thin and revealed a high T2 signal (not shown). Patients (B) DEL2-1 and (C) DEL3-1 have less extensive changes in lobar white matter (B.a–B.e, C.a–C.e). The periventricular area was less affected both in the SE and FLAIR images (B.a and B.b, C.a and C.b, arrows). High SI continued in the corticospinal tract (open arrows) in the internal capsule (B.c and C.c) and the cerebral crura in the mesencephalon (B.d and C.d). Diffusely increased SI was also present in the upper pons (B.e and C.e). Decussations of the superior cerebellar peduncles (B.d and C.d, open arrowhead) had a high SI (B.d and C.d, open arrow). Patient DEL2-1 had larger mesencephalic SI changes (B.d) compared with the other patients. This patient also had cerebral atrophy: very broad third ventricle (B.c), widened lateral ventricles (B.b), and cerebral sulci (B.a–B.e). (D) Patient DEL 3-2 had abnormalities distinct from other patients; the SI was very high locally in the posterior frontal lobes, including corticospinal tracts, on the SE images (D.a and D.b). On the FLAIR images, the central parts of the pathologic areas showed a low SI as a sign of a high fluid content. There were some small separate frontal and parietal lesions that may be of the same or another etiology, whereas very small occipital changes (D.c) were present. The high SI continued downward in the corticospinal tract (D.c and D.d, open arrows) until the cerebral crura but not further. Increased SI in the decussation of the superior cerebellar peduncles was observed (D.d, open arrowhead). FLAIR = fluid-attenuated inversion recovery; SE = conventional or turbo spin-echo sequence; SI = signal intensity.


and partial overlap with ADLD due to *LMNB1* duplications. Clinically, 4/5 patients presented at onset with speech symptoms including dysarthria and hypophonia. This has not been reported for ADLD with *LMNB1* duplications, where the most common presenting feature was autonomic dysfunction. Onset of symptoms also appeared to be earlier in patients with deletions.

On MRI, cerebral white matter involvement was more extensive, especially in the temporal lobes in patients with deletions compared with those with duplications at the same ages. The periventricular rim was less severely affected than other pathologic lobar white matter in both patient groups. The corticospinal tracts were affected in both groups, but only in one of the deletion patients (DEL1-1) did this extend to the medulla oblongata. This was the only 1 of the 4 deletion patients having an abnormality in the cerebellar peduncles. This is in contrast to duplication patients who have early

changes in the medulla oblongata and cerebellar peduncles.² Cerebral atrophy is not a prominent feature in patients with duplications, but marked atrophy was found in 1 of our patients (DEL 2-1) and in the previously reported Italian ADLD-1-TO family.⁸ In patients with deletions, only the uppermost cervical spinal cord was atrophic, and in the 2 patients with a spinal MRI, no obvious SI changes were found in the rest of the cord. In *LMNB1* duplication patients, the entire spinal cord is atrophic, and T2 signal in white matter is pathologic. This difference could explain the lack of early autonomic symptoms in patients with deletions, as it has been hypothesized that autonomic symptoms in ADLD with duplications are due to spinal cord involvement.²

Analysis of the deletion events, which were clearly nonrecurrent, allowed us to define a minimal critical region of ~167 kb that is required for disease causation. Strikingly, this genomic region encompassed a boundary between 2 topologically associated

Figure 2 Pathogenic deletions upstream of *LMNB1*



Schematic diagram of the deletions upstream of the *LMNB1* gene in the 3 reported families. Also shown is the deletion from the previously reported family (ADLD-1-TO) from Giorgio et al. (2015). A comparison between the genomic regions deleted in the different families allowed us to identify the minimal critical region required for the disease phenotype. Note that the critical region spans a 2 putative TADs (TD1 and TD2), and a deletion would result in the disruption of the TAD boundary (TDB). Putative forebrain enhancers are also indicated. TADs were characterized using the 3D Genome Browser (promoter.bx.psu.edu/hic/) on fetal brain-derived data. ADLD = autosomal dominant leukodystrophy; TAD = topologically associated domain.

domains (TADs) and strengthens our original hypothesis that a disruption of the TAD boundary causes *LMNB1* overexpression and in turn the disease.⁶ Sequencing the deletion junctions revealed the importance of repetitive elements (*Alu*, *LINEs*) in the genomic rearrangement. Their presence suggests that either a nonallelic homologous recombination mechanism or a microhomology-mediated break-induced repair type mechanism mediated by repeats is likely to cause the genomic deletions.

The identification of a larger cohort of patients confirms the pathogenic role of deletions upstream of *LMNB1* in the leukodystrophy phenotype. Given that these mutations do not alter the coding sequence, our data also emphasize the importance of regulatory elements and the need for performing analyses for copy number variants that might be missed with the standard whole-exome sequencing, currently being used to identify mutations in patients with leukodystrophies.

Author contributions

C. Toro, A. Brusco, and Q.S. Padiath managed the project. A. Lehman, M.K. Koenig, R. Adejumo, M. Knight, R. Gavrilova, M. Alturkustani, M. Sharma, R. Hammond, W.A. Gahl, and C. Toro performed clinical and radiologic examinations. C. Toro and R. Raininko analyzed and compiled clinical and radiologic data. B. Nmezi and E. Giorgio performed aCGH experiments. B. Nmezi, E. Giorgio, M. Spielmann, A. Brusco, and Q.S. Padiath performed analysis of aCGH and genetic data. B. Nmezi, E. Giorgio, R. Raininko, C. Toro, A. Brusco, and Q.S. Padiath wrote the manuscript with inputs from all authors.

Acknowledgment

The authors thank the patients for their participation. They also thank Dr. Svetlana Yatsenko, the Pittsburgh Cytogenetics

Laboratory, and other members of the Padiath laboratory for technical assistance and helpful discussions.

Study funding

This work was supported by funds from the University of Pittsburgh to B.N., Q.S.P., the Fondazione Umberto Veronesi (postdoctoral fellowship 2017 to E.G.), the “Associazione E. E. Rulfo per la ricerca biomedica” to AB, and the National Institutes of Health (NIH) Common Fund through the NIH Undiagnosed Diseases Program/Undiagnosed Diseases Network.

Disclosure

B. Nmezi reports no disclosures. E. Giorgio holds patents for 3 siRNA sequences targeting a single allele of the human *LaminB1* gene as therapeutic option for Autosomal Dominant Leukodystrophy. R. Raininko reports no disclosures. A. Lehman has received governmental research support from the Canadian Institutes for Health Research; has received academic research support from the Department of Medical Genetics at the University of British Columbia; and has received foundation/society research support from the Rare Disease Foundation and the British Columbia Clinical Genomics Network. M. Spielmann reports no disclosures. M.K. Koenig has served on the scientific advisory board of Novartis Pharmaceuticals; has received travel or speaker funding from Novartis Pharmaceuticals and Lundbeck; serves on the editorial board of the *Journal of Child Neurology*; holds a pending patent for a topical product for treatment of facial angiofibromas in Tuberous Sclerosis Complex; has served on speakers' bureaus of Novartis Pharmaceuticals and Lundbeck; has received commercial research support from Novartis Pharmaceuticals, Reata Pharmaceuticals, EryDel S.p.A., Vtesse, Inc, Pfizer, Retrophin, Stealth, and Ultragenyx Pharmaceutical; has received governmental research support

from the NIH and the Department of Defense; has received foundation/society research support from People Against Leigh's Syndrome; and has received license fee payments from LAM Therapeutics. R. Adejumo has received commercial research support from Ultragenyx Pharmaceutical, Inc., EryDel S.p.A., Stealth BioTherapeutics, Inc, BioElectron Technology Corporation, and Retrophin, Inc; has received academic research support from the University of Texas Mitochondrial Center of Excellence; and has received foundation/society research support from People Against Leigh's Syndrome. M. Knight reports no disclosures. R. Gavrilova has served on the scientific advisory board of the Mitochondrial Medicine Society Board. Murad Alturkustani reports no disclosures. M. Sharma serves on the editorial board of the *Canadian Journal of Neurological Sciences*. Robert Hammond reports no disclosures. W.A. Gahl has received travel funding from the Cystinosis Research Network; serves on the editorial board of *Molecular Genetics and Metabolism*; receives ManNAc licensing royalties; and has received governmental research funding from the NIH. C. Toro is an employee of the NIH. A. Brusco has served on the editorial boards of *Frontiers in Aging Neuroscience* and *Frontiers in Neurology*; holds patents for a new method for SCA1-3,6,7 genetic diagnosis and for allele-specific antisense therapy for ADLD; has received academic research support from the University of Torino; and has received foundation/society

research support from Associazione Emma ed Ernesto Rulfo. Q.S. Padiath reports no disclosures. Full disclosure form information provided by the authors is available with the full text of this article at Neurology.org/NG.

Publication history

Received by *Neurology: Genetics* July 27, 2018. Accepted in final form November 6, 2018.

References

1. Padiath QS, Fu YH. Autosomal dominant leukodystrophy caused by lamin B1 duplications: a clinical and molecular case study of altered nuclear function and disease. *Methods Cell Biol* 2010;98:337–357.
2. Finnsson J, Sundblom J, Dahl N, Melberg A, Raininko R. LMNB1-related autosomal-dominant leukodystrophy: clinical and radiological course. *Ann Neurol* 2015;78:412–425.
3. Nahhas N, Sabet Rasekh P, Vanderver A, Padiath Q. Autosomal dominant leukodystrophy with autonomic disease. In: Pagon RA, Adam MP, Ardinger HH, et al, editors. *GeneReviews*(R). Seattle, WA: University of Washington; 1993.
4. Giorgio E, Rolyan H, Kropp L, et al. Analysis of LMNB1 duplications in autosomal dominant leukodystrophy provides insights into duplication mechanisms and allele-specific expression. *Hum Mutat* 2013;34:1160–1171.
5. Padiath QS, Saigoh K, Schiffmann R, et al. Lamin B1 duplications cause autosomal dominant leukodystrophy. *Nat Genet* 2006;38:1114–1123.
6. Giorgio E, Robyr D, Spielmann M, et al. A large genomic deletion leads to enhancer adoption by the lamin B1 gene: a second path to autosomal dominant adult-onset demyelinating leukodystrophy (ADLD). *Hum Mol Genet* 2015;24:3143–3154.
7. Alturkustani M, Sharma M, Hammond R, Ang LC. Adult-onset leukodystrophy: review of 3 clinicopathologic phenotypes and a proposed classification. *J Neuropathol Exp Neurol* 2013;72:1090–1103.
8. Bergui M, Bradac GB, Leombruni S, Vaula G, Quattrocchio G. MRI and CT in an autosomal-dominant, adult-onset leukodystrophy. *Neuroradiology* 1997;39:423–426.

Neurology[®] Genetics

Genomic deletions upstream of lamin B1 lead to atypical autosomal dominant leukodystrophy

Bruce Nmezi, Elisa Giorgio, Raili Raininko, et al.

Neurol Genet 2019;5;

DOI 10.1212/NXG.0000000000000305

This information is current as of January 24, 2019

Neurol Genet is an official journal of the American Academy of Neurology. Published since April 2015, it is an open-access, online-only, continuous publication journal. Copyright © 2019 The Author(s). Published by Wolters Kluwer Health, Inc. on behalf of the American Academy of Neurology. All rights reserved. Online ISSN: 2376-7839.



Updated Information & Services	including high resolution figures, can be found at: http://ng.neurology.org/content/5/1/e305.full.html
References	This article cites 7 articles, 0 of which you can access for free at: http://ng.neurology.org/content/5/1/e305.full.html##ref-list-1
Subspecialty Collections	This article, along with others on similar topics, appears in the following collection(s): All Clinical Neurology http://ng.neurology.org/cgi/collection/all_clinical_neurology All Demyelinating disease (CNS) http://ng.neurology.org/cgi/collection/all_demyelinating_disease_cns All Genetics http://ng.neurology.org/cgi/collection/all_genetics Autonomic diseases http://ng.neurology.org/cgi/collection/autonomic_diseases MRI http://ng.neurology.org/cgi/collection/mri
Permissions & Licensing	Information about reproducing this article in parts (figures,tables) or in its entirety can be found online at: http://ng.neurology.org/misc/about.xhtml#permissions
Reprints	Information about ordering reprints can be found online: http://ng.neurology.org/misc/addir.xhtml#reprintsus

Neurol Genet is an official journal of the American Academy of Neurology. Published since April 2015, it is an open-access, online-only, continuous publication journal. Copyright © 2019 The Author(s). Published by Wolters Kluwer Health, Inc. on behalf of the American Academy of Neurology.. All rights reserved. Online ISSN: 2376-7839.

