

Jens Reimann, MD*
Diana Lehmann, MD*
Steven A. Hardy, PhD
Gavin Falkous, MPhil
Charlotte V.Y. Knowles,
MBiolSci
Rachel L. Jones, BSc
Wolfram S. Kunz, PhD
Robert W. Taylor, PhD,
FRCPATH*
Cornelia Kornblum,
MD*

Neurol Genet
2017;3:e147; doi: 10.1212/
NXG.000000000000147

CAMPTOCORMIA AND SHUFFLING GAIT DUE TO A NOVEL MT-TV MUTATION: DIAGNOSTIC PITFALLS

OPEN

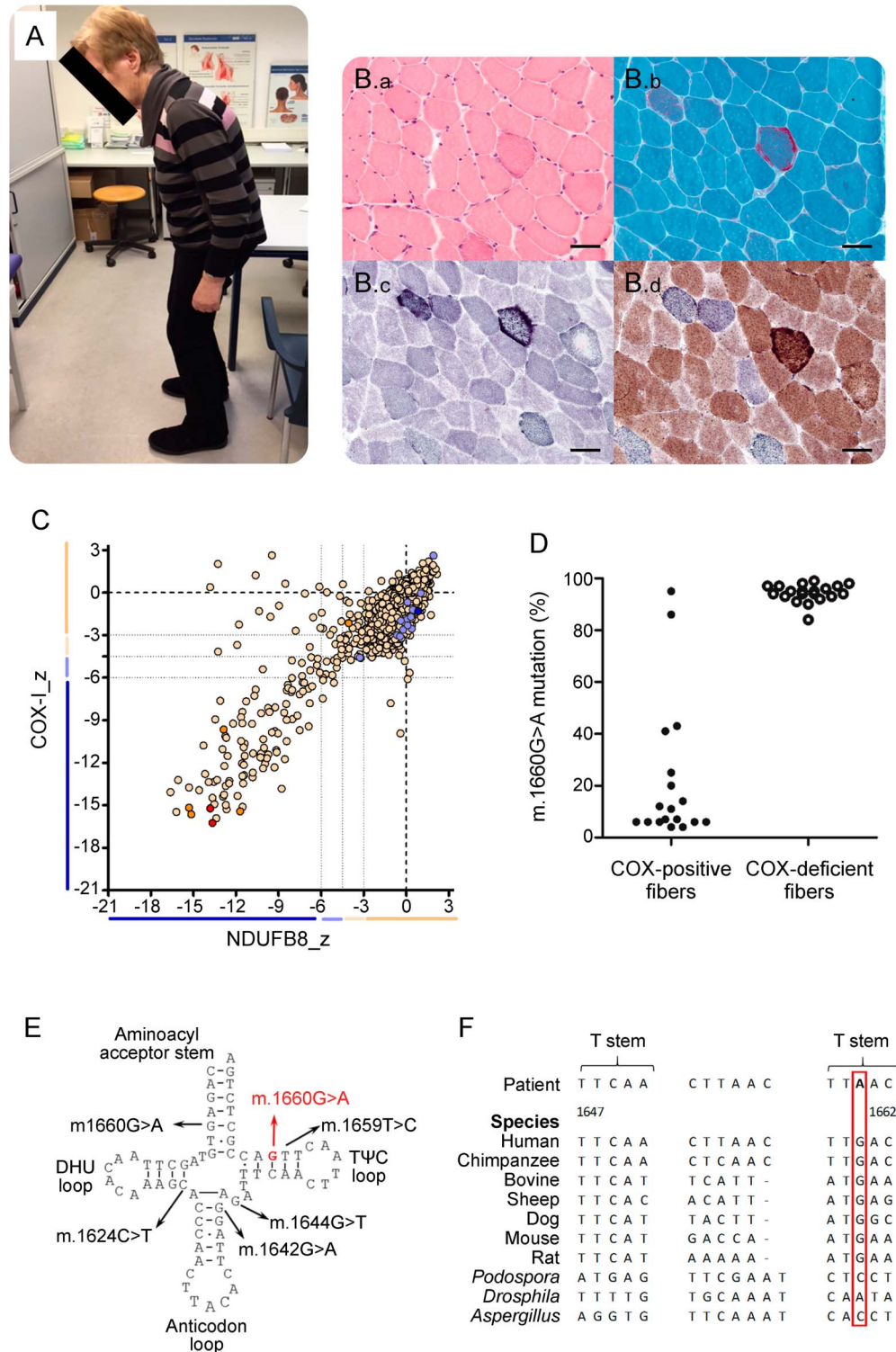
Camptocormia, the disabling flexion of the spine in upright, but not supine position, has been reported in a range of central nervous and neuromuscular conditions and is associated with aging, too. In many cases, e.g., Parkinson disease, further clinical symptoms will clarify its association, if not pathophysiology. In others, a tangle of signs and symptoms obscures the etiology. Here, we present a new solution to this challenging and complex clinical problem.

A 71-year-old Caucasian woman presented with a 3-year history of unstable, short-stepping slow, shuffling gait and complained of deteriorating handwriting. Her medical history included basalioma, malignant melanoma, hypothyreosis, bilateral cataract and hypoacusis, gastroesophageal reflux, prediabetes, and thoracic and lumbar disc herniation. While her mother and a brother suffer from type II diabetes and a sister has a thyroid disorder, no other recurrent, neuromuscular, or movement disorders are known in the family. A brother died in childhood of unclear causes, a further brother in adulthood of a liver condition. Her son, daughter, and 2 grandsons are well. Clinical examination revealed slow horizontal saccades. Deep tendon reflexes were brisk, but for diminished ankle reflexes. Babinski response was equivocal on the right. Muscle tone and bulk appeared normal, but there was weakness of proximal lower limb muscles and foot extensors (MRC 4). Steps were short and their number for 180° turn increased. Positive Romberg test and inability to tandem walking suggested sensory ataxia, but sensory examination was otherwise normal. At follow-up, a slightly stooped posture progressed into camptocormia (figure, A) without signs of dystonia or muscle rigidity. Mild weakness of proximal arm muscles was found. Spinal MRI showed cervical stenosis without signs of myelopathy, but fatty replacement of paraspinal muscles. Initial neurophysiologic examinations showed prolonged cortical latency after tibial nerve stimulation, but transcranial stimulation gave normal total and central motor conduction times, and EMG of the

vastus lateralis muscle was normal. Repeated neurography revealed a mild sensorimotor polyneuropathy. Levodopa treatment and CSF drainage under the suspicion of Parkinson disease or normal pressure hydrocephalus (NPH) due to enlarged lateral ventricles in an otherwise unremarkable brain MRI and urge incontinence were unsuccessful. DAT scan, EEG, Holter ECG, blood pressure monitoring, orthostatic test, and CSF analysis, including biomarkers for neurodegeneration (beta-amyloid, tau, and phospho-tau), revealed no abnormalities. Mini-Mental State examination and Montreal Cognitive Assessment indicated mild cognitive impairment. Maximum serum creatine kinase was 236 U/L (<170 U/L). Genetic and antibody analysis ruled out facioscapulohumeral muscular dystrophy types 1 and 2 as well as myasthenic syndromes, respectively.

Biceps brachii muscle biopsy showed angular atrophic fibers, a few degenerating fibers and increased lipofuscin deposition. Modified Gomori trichrome staining and oxidative enzyme reactions revealed ragged red fibers and ~6% cytochrome *c* oxidase (COX)-deficient fibers (figure, B). Occasional ragged red fibers appeared COX positive. In skeletal muscle tissue homogenate, activities of mitochondrial respiratory chain complexes I and IV normalized against citrate synthase activity were mildly decreased to 0.07 (controls: 0.11 ± 0.03 [n = 11]) and 1.38 (2.7 ± 0.5 [n = 11]) U/g, respectively, while quadruple OXPHOS immunofluorescence¹ confirmed the presence of fibers lacking both complex I (NDUFB8) and complex IV (COX-1) expression, confirming a multiple respiratory chain defect (figure, C). Mitochondrial DNA (mtDNA) sequencing revealed a previously unreported heteroplasmic m.1660G>A *MT-TV* variant present at highest levels in the muscle (35% mutation load), with lower levels in urinary epithelial sediments (13%) and blood (9%), consistent with the segregation pattern of a pathogenic mtDNA mutation. Single-fiber segregation studies clearly confirmed pathogenicity, showing a statistically significant higher m.1660G>A mutation load in COX-deficient fibers (94.30 ± 0.76 [n = 20]) than in COX-positive fibers (22.17 ± 6.49 [n = 18], $p < 0.0001$, unpaired *t* test) (figure, D).

Figure Clinical, histopathologic, and molecular genetic characterization of the m.1660G>A MT-TV mutation



(A) Camptocormia as the main clinical feature of the patient harboring the novel 1660G>A MT-TV mutation. (B) Serial hematoxylin and eosin (B.a), modified Gomori trichrome staining (B.b), succinate dehydrogenase (SDH) (B.c), and cytochrome c oxidase (COX)-SDH histochemistry (B.d) showing ragged red fibers and COX-deficient fibers (scale bar = 50 μ m). (C) Result of the quadruple OXPHOS immunofluorescence analysis, confirming the presence of fibers lacking both complex I (NDUFB8) and complex IV (COX-1) expressions. (D) Single muscle fiber mutation load segregation. The graph shows the mutation load measured in individual COX-positive (closed dots) and COX-deficient fibers (open dots) laser microdissected from the patient muscle biopsy. (E) Schematic representation of the cloverleaf structure of the mitochondrial (mt)-tRNA Val molecule and the corresponding location of the pathogenic mutation (marked in red) and previous reported mt-tRNA Val mutations (black). (F) Phylogenetic conservation of the appropriate regions of the mt-tRNA Val gene sequence for the m.1660G>A mutation.

Camptocormia has been reported in association with myopathic and mitochondrial defects^{2–7} with recent research suggesting limb muscle biopsy as a recommended diagnostic procedure.⁷ Here, we demonstrate a rare late-onset mitochondrial disorder due to a novel pathogenic *MT-TV* mutation (figure, E and F) mimicking much more common clinical conditions like NPH, subcortical arterosclerotic encephalopathy, or extrapyramidal movement disorders. Particularly, the coexistence of a shuffling gait, peripheral neuropathy, axial weakness, and bent spine at an advanced age may masquerade a mitochondrial pathophysiology and lead to erroneous diagnosis and treatment. Our finding adds to the spectrum of differential diagnostic considerations in gait and balance disorders in the elderly and underlines the importance of skeletal muscle biopsy as a major diagnostic tool in these patients. Mitochondrial disorders frequently lead to multisystemic disease and may manifest even in late adulthood where symptomatic treatment options and tailored clinical advice are of utmost importance for affected patients.

*These authors contributed equally to the manuscript.

From the Department of Neurology (J.R., C.K.), Department of Epileptology (W.S.K.), Life and Brain Centre (W.S.K.), and Centre for Rare Diseases Bonn (ZSEB) (C.K.), University Hospital of Bonn, Germany; Department of Neurology (D.L.), University of Halle/S., Germany; and Wellcome Trust Centre for Mitochondrial Research (D.L., S.A.H., G.F., C.V.Y.K., R.L.J., R.W.T.), Institute of Neuroscience, The Medical School, Newcastle University, Newcastle upon Tyne, UK.

Author contributions: J.R.: analysis and interpretation of the clinical and histological data and drafting and revision of the manuscript. D.L.: analysis and interpretation of immunohistochemical and molecular genetic data, preparation of manuscript and figures, and statistical analysis. S.A.H.: analysis and interpretation of molecular genetic data. G.F.: analysis and interpretation of histochemical and histological data. C.V.Y.K. and R.L.J.: analysis and interpretation of biochemical and genetic data. W.S.K.: analysis and interpretation of biochemical and genetic data. R.W.T.: drafting and revision of the manuscript and figures for important intellectual content and study supervision and coordination. C.K.: analysis or interpretation of the clinical data, drafting and revision of the manuscript, and study coordination.

Acknowledgment: The authors thank Mrs. Karin Kappes-Horn, Department of Neurology, University Hospital of Bonn, Germany, for her invaluable technical assistance with the diagnostic histopathology and respiratory chain biochemistry.

Study funding: This study was funded by a Wellcome Trust Strategic Award (096919Z/11/Z).

Disclosure: Dr. Reimann serves as an associate editor for BMC Neurology. Dr. Lehmann receives funding from the European Academy of Neurology. Dr. Hardy, Mr. Falkous, Ms. Knowles, and Ms. Jones report no disclosures. Prof. Kunz is supported by the Deutsche Forschungsgemeinschaft (KU911/21-1). Prof. Taylor is supported by the Wellcome Trust Centre for Mitochondrial Research (096919Z/11/Z), the MRC Centre for Translational Research in Neuromuscular Disease Mitochondrial Disease Patient Cohort (UK) (G0800674), the Lily Foundation, the UK NIHR Biomedical Research Centre for Aging and Age-related disease award to the Newcastle upon Tyne Foundation Hospitals NHS Trust, and the UK NHS Highly Specialized “Rare Mitochondrial Disorders of Adults and Children” Service. Prof. Kornblum has received travel grants and honoraria for clinical advisory board activities from Stealth Biotherapeutics; has received travel grants and speaker honoraria from Sanofi Genzyme; has received travel grants from Mari-gold Foundation Canada and Deutsche Gesellschaft für Muskelkranke e.V.; and has received funding from the German Ministry of Education and Research (BMBF: 01GM0862), the Deutsche Gesellschaft für Muskelkranke e.V. (Me4/1), and the Mari-gold Foundation, Canada. Go to Neurology.org/ng for full disclosure forms. The Article Processing Charge was funded by the Wellcome Trust.

This is an open access article distributed under the terms of the Creative Commons Attribution License 4.0 (CC BY), which permits unrestricted use, distribution, and reproduction in any medium, provided the original work is properly cited.

Received November 29, 2016. Accepted in final form February 24, 2017.

Correspondence to Dr. Reimann: jens.reimann@ukb.uni-bonn.de

1. Rocha MC, Grady JP, Grunewald A, et al. A novel immunofluorescent assay to investigate oxidative phosphorylation deficiency in mitochondrial myopathy: understanding mechanisms and improving diagnosis. *Sci Rep* 2015;5:15037.
2. Sakiyama Y, Okamoto Y, Higuchi I, et al. A new phenotype of mitochondrial disease characterized by familial late-onset predominant axial myopathy and encephalopathy. *Acta Neuropathol* 2011;121:775–783.
3. Delcey V, Hachulla E, Michon-Pasturel U, et al. Camptocormia: a sign of axial myopathy: report of 7 cases [in French]. *Rev Med Interne* 2002;23:144–154.
4. Gomez-Puerta JA, Peris P, Grau JM, Martinez MA, Guanabens N. Camptocormia as a clinical manifestation of mitochondrial myopathy. *Clin Rheumatol* 2007;26:1017–1019.
5. Schabitz WR, Glatz K, Schuhan C, et al. Severe forward flexion of the trunk in Parkinson’s disease: focal myopathy of the paraspinal muscles mimicking camptocormia. *Mov Disord* 2003;18:408–414.
6. Serratrice G, Pouget J, Pellissier JF. Bent spine syndrome. *J Neurol Neurosurg Psychiatry* 1996;60:51–54.
7. Chanson JB, Lannes B, Echaniz-Laguna A. Is deltoid muscle biopsy useful in isolated camptocormia? A prospective study. *Eur J Neurol* 2016;23:1086–1092.

Neurology[®] Genetics

Camptocormia and shuffling gait due to a novel *MT-TV* mutation: Diagnostic pitfalls

Jens Reimann, Diana Lehmann, Steven A. Hardy, et al.

Neurol Genet 2017;3;

DOI 10.1212/NXG.0000000000000147

This information is current as of April 5, 2017

Updated Information & Services	including high resolution figures, can be found at: http://ng.neurology.org/content/3/3/e147.full.html
References	This article cites 7 articles, 1 of which you can access for free at: http://ng.neurology.org/content/3/3/e147.full.html##ref-list-1
Subspecialty Collections	This article, along with others on similar topics, appears in the following collection(s): Mitochondrial disorders http://ng.neurology.org/cgi/collection/mitochondrial_disorders Muscle disease http://ng.neurology.org/cgi/collection/muscle_disease
Permissions & Licensing	Information about reproducing this article in parts (figures, tables) or in its entirety can be found online at: http://ng.neurology.org/misc/about.xhtml#permissions
Reprints	Information about ordering reprints can be found online: http://ng.neurology.org/misc/addir.xhtml#reprintsus

Neurol Genet is an official journal of the American Academy of Neurology. Published since April 2015, it is an open-access, online-only, continuous publication journal. Copyright © 2017 The Author(s). Published by Wolters Kluwer Health, Inc. on behalf of the American Academy of Neurology. All rights reserved. Online ISSN: 2376-7839.

