

Homozygosity for *SCN4A* Arg1142Gln causes congenital myopathy with variable disease expression

Christine K. Sloth, MD, Federico Denti, PhD, Nicole Schmitt, PhD, Bo Hjorth Bentzen, PhD, Christina Fagerberg, MD, John Vissing, DMSci, and David Gaist, PhD

Correspondence

Prof. Gaist
dgaist@health.sdu.dk

Neurol Genet 2018;4:e267. doi:10.1212/NXG.0000000000000267

Congenital myopathy has recently been associated with biallelic pathogenic variants in the *SCN4A* gene that encodes the voltage-dependent sodium channel Na_v1.4.^{1,2} In 13 previously reported cases,^{1,2} 7 died *in utero* or shortly after birth. The 6 survivors showed features consistent with “classical” congenital myopathy. Here, we report 2 new familial cases with variable phenotype.

Written informed consent was obtained from both patients. Permission for the study was granted by the Danish Data Protection Agency.

The index patient, an 18-year-old woman, born as the second of 2 children to consanguineous parents, reported weakness and dyspnea from early childhood. Pregnancy and birth were normal, but postpartum, she had dysphagia and was tube fed. Early motor milestones were delayed, with independent ambulation achieved at age 2.25 years and inability to lift her head from a supine position until age 3 years. She experienced improvement in her condition throughout childhood, but still had reduced walking distance (2.5 km), difficulty lifting heavy objects, and experienced patella luxations.

On examination, the patient is 150 cm tall and has a dolichocephalic head shape and elbow hypermobility (figure 1A). Strength testing showed diffuse muscle force reduction at Medical Research Council (MRC) grade 4, with no distal/proximal gradient, and axial weakness. Spirometry showed normal forced vital capacity (FVC) (88%) and forced expiratory volume (FEV1) (96%).

Creatine kinase (CK) levels and neurophysiologic findings were normal. Replacement of muscle by fat on MRI was pronounced in gluteus maximus and hamstring muscles (figure 1B). Muscle biopsy, at age 4 years, displayed myopathic features with varying fiber size, increased number of internalized nuclei, atrophic fibers, and endomysial fibrosis and fat infiltration.

Next-generation sequencing revealed homozygosity for a previously described missense variant in *SCN4A* (NM_000334.4: c.3425G>A(p.Arg.1142Gln)),² confirmed through Sanger sequencing, and was deemed to be pathogenic by 6 prediction tools. Parents were heterozygous for the variant.

The 22-year-old sister of the index patient was also homozygous for Arg1142Gln. She had milder muscular complaints than her sister, which included difficulties lifting her head when lying down, exertional shortness of breath, and poor cycling capacity since childhood. She had elbow joint hypermobility like her sister. Her motor milestones were normal. Strength testing

From the Department of Neurology (C.K.S., D.G.), Odense University Hospital; and Department of Clinical Research (C.K.S., D.G.), Faculty of Health Sciences, University of Southern Denmark, Odense; Department of Biomedical Sciences (F.D., N.S., B.H.B.), Faculty of Health and Medical Sciences, University of Copenhagen; Department of Clinical Genetics (C.F.), Odense University Hospital; and Copenhagen Neuromuscular Center, Department of Neurology (J.V.), Rigshospitalet, University of Copenhagen, Denmark.

Funding information and disclosures are provided at the end of the article. Full disclosure form information provided by the authors is available with the full text of this article at Neurology.org/NG.

The Article Processing Charge was funded by the authors.

This is an open access article distributed under the terms of the Creative Commons Attribution-NonCommercial-NoDerivatives License 4.0 (CC BY-NC-ND), which permits downloading and sharing the work provided it is properly cited. The work cannot be changed in any way or used commercially without permission from the journal.

Figure 1 Clinical features in sisters with SCN4A congenital myopathy

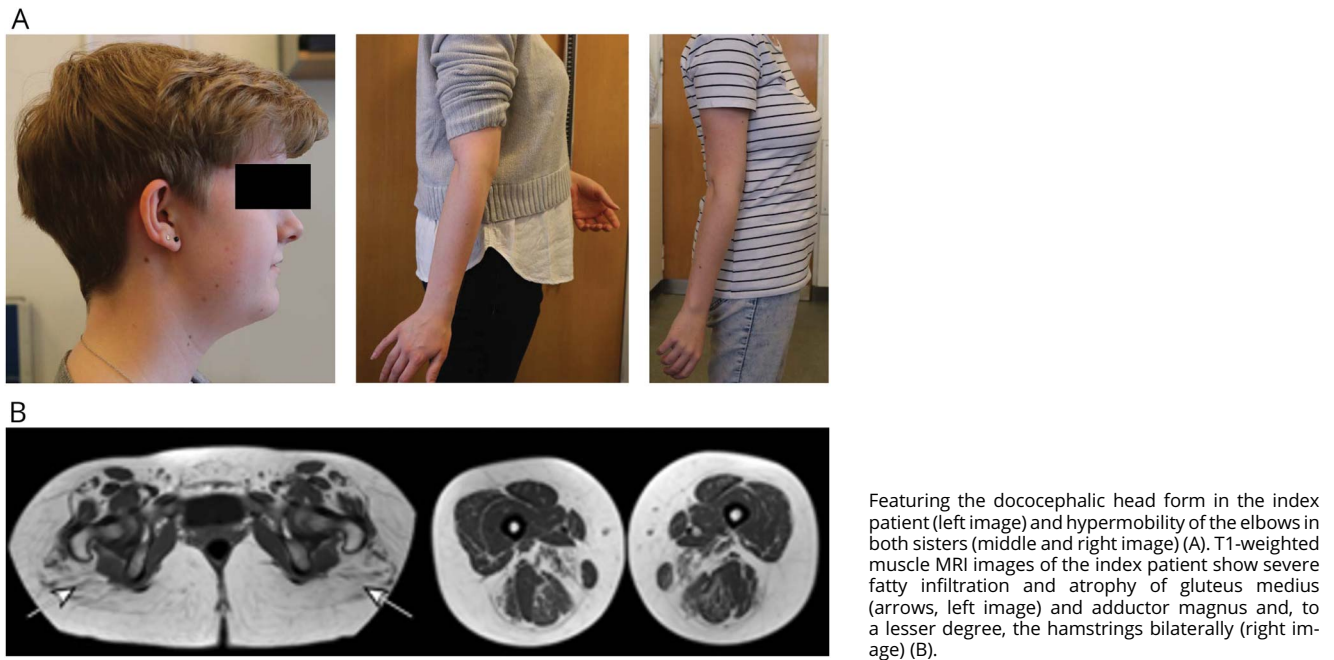
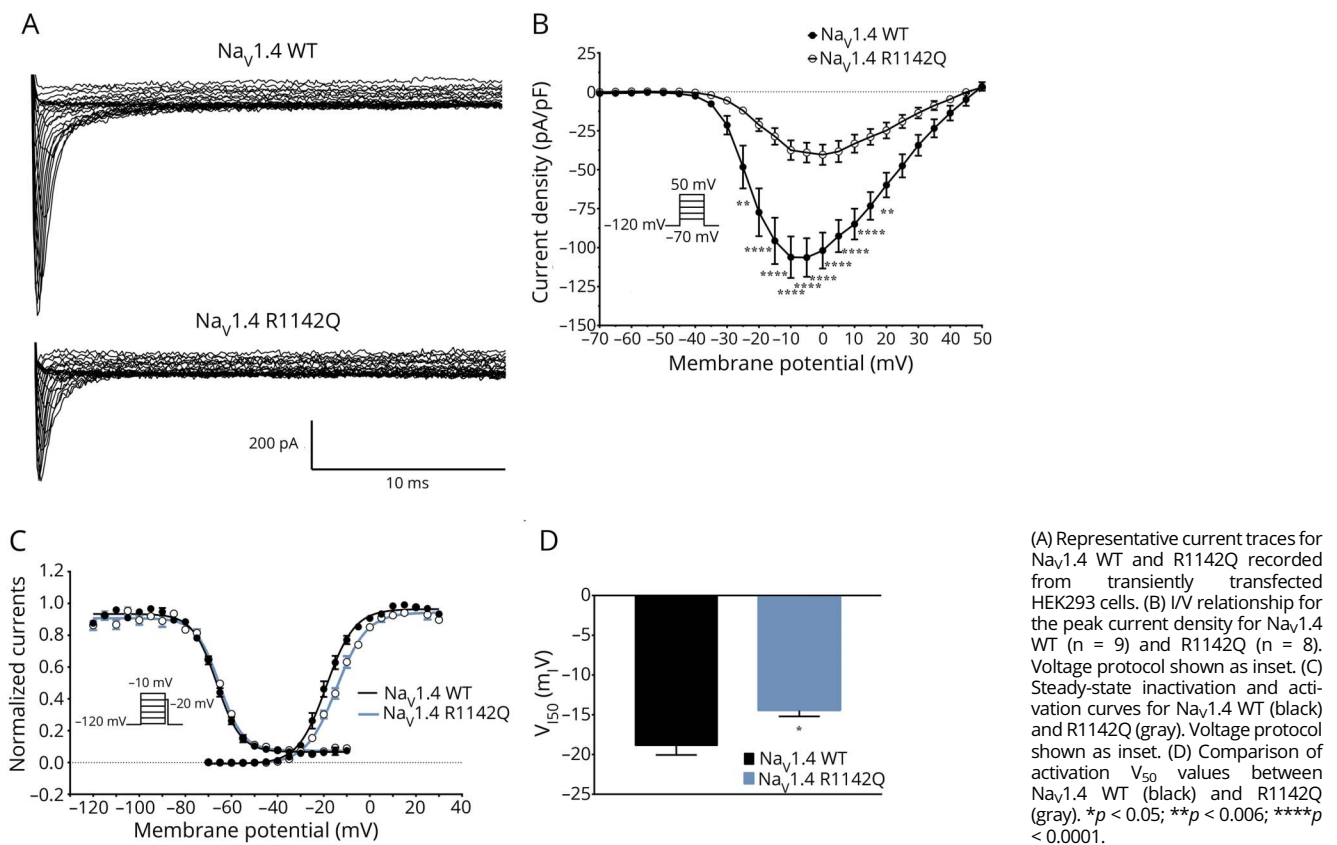


Figure 2 The mutation R1142Q causes loss-of-function of $Na_v1.4$ current



showed reduced neck flexion (MRC 4+), shoulder abduction (MRC4+), and hip flexion (MRC 4+). CK, lung function tests, and MRI of thigh muscles were normal.

Functional assessment of the Arg1142Gln (R1142Q) variant in human embryonic kidney 293 (HEK293) cells revealed partial loss-of-function effects (figure 2), as previously reported in SCN4A-related congenital myopathy.^{1,2} Na_v1.4 R1142Q peak current density was significantly lower than wild type (WT) (WT: 106.4 ± 12.4 pA/pF, R1142Q: -39.0 ± 6.4 pA/pF at 5 mV, figure 2, A and B), and the voltage dependence of channel activation was significantly changed (figure 2, C and D).

Variants in SCN4A were originally linked to congenital myasthenia,^{3,4} but recently, also to severe fetal hypokinesia and early lethality¹ and to sudden infant death syndrome.⁵ A strikingly milder phenotype of “classical” congenital myopathy has been described in 6 patients with SCN4A variants in a recessive pattern, only 3 of whom were adults (aged 18–35 years old).^{1,2} Our 18-year-old index patient exhibited a phenotype similar to that previously reported,¹ while her 20-year-old sister was only marginally affected. Our index patient’s characteristic muscle MRI findings were similar to 4 other patients with SCN4A mutations, including 2 brothers, compound heterozygous for c.3425G>A (p.Arg1142Gln) and another missense variant c.1123T>C (p.Cys375Arg).^{1,2} The brothers, unlike our patients, had elongated faces, ptosis, facial weakness, scoliosis, and elevated CK.² We speculate whether homozygosity for the p.Arg1142Gln variant conferred the milder phenotype observed in our patients. The present report expands our knowledge regarding SCN4A-related congenital myopathy in adulthood and underscores that the phenotype of this disorder may vary considerably, even within members of the same family, as in other recessive channelopathies affecting muscles.⁶

Author contributions

C.K. Sloth: drafted the manuscript and performed administrative work. F. Denti: tested the effect of the SCN4A mutation in a cell line. N. Schmitt: tested the effect of the SCN4A mutation in a cell line, interpreted data, revised the manuscript, and drafted figures. B.H. Bentzen: tested the effect of the SCN4A mutation in a cell line. C. Fagerberg: in charge of DNA-testing of the 2 sisters and revised the manuscript.

J. Vissing and D. Gaist: design, revised the manuscript, interpreted clinical data, and drafted figures.

Study funding

This study did not receive external funding.

Disclosure

C.K. Sloth, F. Denti, N. Schmitt, B.H. Bentzen, and C. Fagerberg report no disclosures. J. Vissing has served on the scientific advisory boards of Sanofi Genzyme, aTyr Pharma, Ultragenyx Pharmaceuticals, Santhera Pharmaceuticals, Sarepta Therapeutics, Audentes Therapeutics, Novo Nordisk, Alexion Pharmaceuticals, and Stealth BT; has received travel funding and speaker honoraria from Sanofi Genzyme, Ultragenyx Pharmaceuticals, Santhera Pharmaceuticals, and aTyr Pharma; serves on the editorial boards of *Neuromuscular Disorders* and the *Journal of Neuromuscular Diseases*; has been a consultant for Sanofi Genzyme, Ultragenyx Pharmaceuticals, Santhera Pharmaceuticals, and aTyr Pharma; and has received research support from the Danish Medical Research Council, the University of Copenhagen, the Augustinus Foundation, the NOVO Nordic Foundation, and the Lundbeck Foundation. D. Gaist has received honoraria from AstraZeneca (Sweden) for participation as a coinvestigator in a research project and has received research support from the Danish Cancer Society. Full disclosure form information provided by the authors is available with the full text of this article at Neurology.org/NG.

Received June 26, 2018. Accepted in final form July 26, 2018.

References

1. Zaharieva IT, Thor MG, Oates EC, et al. Loss-of-function mutations in SCN4A cause severe foetal hypokinesia or “classical” congenital myopathy. *Brain J Neurol* 2016;139:674–691.
2. Gonorazky HD, Marshall CR, Al-Murshed M, et al. Congenital myopathy with “corona” fibres, selective muscle atrophy, and craniosynostosis associated with novel recessive mutations in SCN4A. *Neuromuscul Disord* 2017;27:574–580.
3. Tsujino A, Maertens C, Ohno K, et al. Myasthenic syndrome caused by mutation of the SCN4A sodium channel. *Proc Natl Acad Sci USA* 2003;100:7377–7382.
4. Arnold WD, Feldman DH, Ramirez S, et al. Defective fast inactivation recovery of Nav 1.4 in congenital myasthenic syndrome. *Ann Neurol* 2015;77:840–850.
5. Männikkö R, Wong L, Tester DJ, et al. Dysfunction of NaV1.4, a skeletal muscle voltage-gated sodium channel, in sudden infant death syndrome: a case-control study. *Lancet* 2018;391:1483–1492.
6. Sahin I, Erdem HB, Tan H, Tatar A. Becker’s myotonia: novel mutations and clinical variability in patients born to consanguineous parents. *Acta Neurol Belg Epub* 2018 Feb 26.

Neurology[®] Genetics

Homozygosity for *SCN4A* Arg1142Gln causes congenital myopathy with variable disease expression

Christine K. Sloth, Federico Denti, Nicole Schmitt, et al.

Neurol Genet 2018;4;

DOI 10.1212/NXG.0000000000000267

This information is current as of September 19, 2018

Updated Information & Services	including high resolution figures, can be found at: http://ng.neurology.org/content/4/5/e267.full.html
References	This article cites 5 articles, 1 of which you can access for free at: http://ng.neurology.org/content/4/5/e267.full.html##ref-list-1
Subspecialty Collections	This article, along with others on similar topics, appears in the following collection(s): Ion channel gene defects http://ng.neurology.org/cgi/collection/ion_channel_gene_defects Muscle disease http://ng.neurology.org/cgi/collection/muscle_disease
Permissions & Licensing	Information about reproducing this article in parts (figures, tables) or in its entirety can be found online at: http://ng.neurology.org/misc/about.xhtml#permissions
Reprints	Information about ordering reprints can be found online: http://ng.neurology.org/misc/addir.xhtml#reprintsus

Neurol Genet is an official journal of the American Academy of Neurology. Published since April 2015, it is an open-access, online-only, continuous publication journal. Copyright © 2018 The Author(s). Published by Wolters Kluwer Health, Inc. on behalf of the American Academy of Neurology. All rights reserved. Online ISSN: 2376-7839.

