

Chorea-acanthocytosis

Homozygous 1-kb deletion in *VPS13A* detected by whole-genome sequencing

Susan Walker, PhD, Rubina Dad, MPhil, Bhooma Thiruvahindrapuram, MSc, Muhammed Ikram Ullah, PhD, Arsalan Ahmad, MD, Muhammad Jawad Hassan, PhD, Stephen W. Scherer, PhD, and Berge A. Minassian, MD

Neurol Genet 2018;4:e242. doi:10.1212/NXG.0000000000000242

Correspondence

Dr. Minassian
Berge.Minassian@
UTSouthwestern.edu

Abstract

Objective

To determine a molecular diagnosis for a large multigenerational family of South Asian ancestry with seizures, hyperactivity, and episodes of tongue biting.

Methods

Two affected individuals from the family were analyzed by whole-genome sequencing on the Illumina HiSeq X platform, and rare variants were prioritized for interpretation with respect to the phenotype.

Results

A previously undescribed, 1-kb homozygous deletion was identified in both individuals sequenced, which spanned 2 exons of the *VPS13A* gene, and was found to segregate in other family members.

Conclusions

VPS13A is associated with autosomal recessive chorea-acanthocytosis, a diagnosis consistent with the phenotype observed in this family. Whole-genome sequencing presents a comprehensive and agnostic approach for detecting diagnostic mutations in families with rare neurologic disorders.

From the Centre for Applied Genomics (S.W., B.T., S.W.S.), The Hospital for Sick Children; Program in Genetics and Genome Biology (S.W., R.D., B.T., S.W.S., B.A.M.), The Hospital for Sick Children, Toronto, Ontario, Canada; Atta-ur Rahman School of Applied Biosciences (R.D., M.J.H.), National University of Sciences and Technology (NUST), Islamabad; Department of Biochemistry (I.M.U.), University of Health Sciences, Lahore; Division of Neurology (A.A.), Shifa International Hospital, Shifa Tameer e Millat University, Islamabad, Pakistan; Department of Molecular Genetics (S.W.S.), University of Toronto; McLaughlin Centre (S.W.S.), University of Toronto, Canada; and Department of Pediatrics (B.A.M.), University of Texas Southwestern, Dallas.

Funding information and disclosures are provided at the end of the article. Full disclosure form information provided by the authors is available with the full text of this article at Neurology.org/NG.

The Article Processing Charge was funded by the authors.

This is an open access article distributed under the terms of the Creative Commons Attribution-NonCommercial-NoDerivatives License 4.0 (CC BY-NC-ND), which permits downloading and sharing the work provided it is properly cited. The work cannot be changed in any way or used commercially without permission from the journal.

Glossary

CHAC = chorea-acanthocytosis; WGS = whole-genome sequencing.

Chorea-acanthocytosis (CHAC; MIM number 200150) is an autosomal recessive neurodegenerative disorder characterized by chorea and blood cells with abnormal morphology (acanthocytosis). Additional common features include dystonia, seizures, tics, and uncontrollable tongue biting. CHAC is caused by homozygous or compound heterozygous mutations in *VPS13A*,¹ which encodes chorein, a protein of unknown function. Here, we report a family with previously unexplained epilepsy found by whole-genome sequencing (WGS) to carry a novel mutation in *VPS13A*, leading to a diagnosis of CHAC.

Clinical report

A large multigeneration Pakistani family was recruited from the province of Khyber Pakhtunkhwa, Pakistan, presenting with a history of seizures, episodes of hyperactive and psychiatric problems and headache, nausea, sleep problems, and persistent tics with onset beginning late in the third decade of life. Within the family, there are 4 affected individuals across 3 generations and an additional younger participant suspected to be in the early stages of developing the same disorder.

Clinical details of index case IV:16

The index patient, a 37-year-old woman, first visited the neurologist at Shifa International Hospital, Islamabad, presenting with hyperactive behavior beginning 1 year prior, with episodes of tongue biting commencing 6 months later and 3 generalized tonic-clonic seizures during the month before the consultation. She had been diagnosed with epilepsy and migraine 3 years earlier but since developed hyperactivity and difficulty in concentrating in daily activities. She also suffered frequent tongue bites while speaking. On examination, she was found to have bilateral ptosis, but other cranial nerves were normal. Tone and power in all 4 limbs were normal, as were plantar responses. Higher mental function and speech were also typical. She was diagnosed as having a congenital syndrome with epilepsy, Tourette syndrome, and bilateral ptosis and prescribed escitalopram, procyclidine, carbamazepine, and later, haloperidol. One genetic test was sent for, namely Huntington disease, for which CAG repeats at the *HD* locus were normal (27 repeats). Red blood cell morphology was studied and reported normal.

Her parents were reportedly nonrelated, and the symptoms were also present in 3 other family members: participants III:1, IV:13, and V:8 in the figure. Individual V:6 was also suspected of being in the early stages of developing the same disorder. The family history and clinical features of affected individuals are described in table 1. Six additional family members (individuals III:16, III:21, V:2, V:4, V:9, and V:13

[figure]) were suspected to have a clinically separate neurologic disorder with symptoms including intellectual disability, seizures, migraine, depression, and osteoarthritis.

Methods

DNA from 22 family members, including the 5 affected individuals, was extracted from whole blood using a standard phenol-chloroform method. Participants III-1 and IV-16 (index case) were selected for analysis by WGS. WGS was performed at The Centre for Applied Genomics (Toronto, Canada) with total genomic DNA following standard protocols. Library preparation was performed from 100 ng of DNA using the Illumina TruSeq Nano DNA Library Prep Kit following the manufacturer's recommended protocol. Libraries were pooled in equimolar quantities and sequenced on an Illumina HiSeq X platform following Illumina's recommended protocol to generate paired-end reads of 150 bases in length. Base calling and data analysis were performed using Illumina HiSeq Analysis Software version 2-2.5.55.1311. Reads were mapped to the hg19 reference sequence using Isaac alignment software (Isaac alignment software: SAAC00776.15.01.27), and SNV and small indel variants were called using the Isaac variant caller (Isaac Variant Caller [Starling]: 2.1.4.2). Rare variants were defined as those with less than 1% frequency in population databases.²⁻⁴ CNVs were detected using the read depth methods as previously described.⁵ Rare CNVs were defined as those less than 1% frequency among unrelated, unaffected individuals sequenced using the same technology.⁶ Participants were screened for regions of homozygosity using PLINK (v1.90) "Runs of homozygosity" implementation.

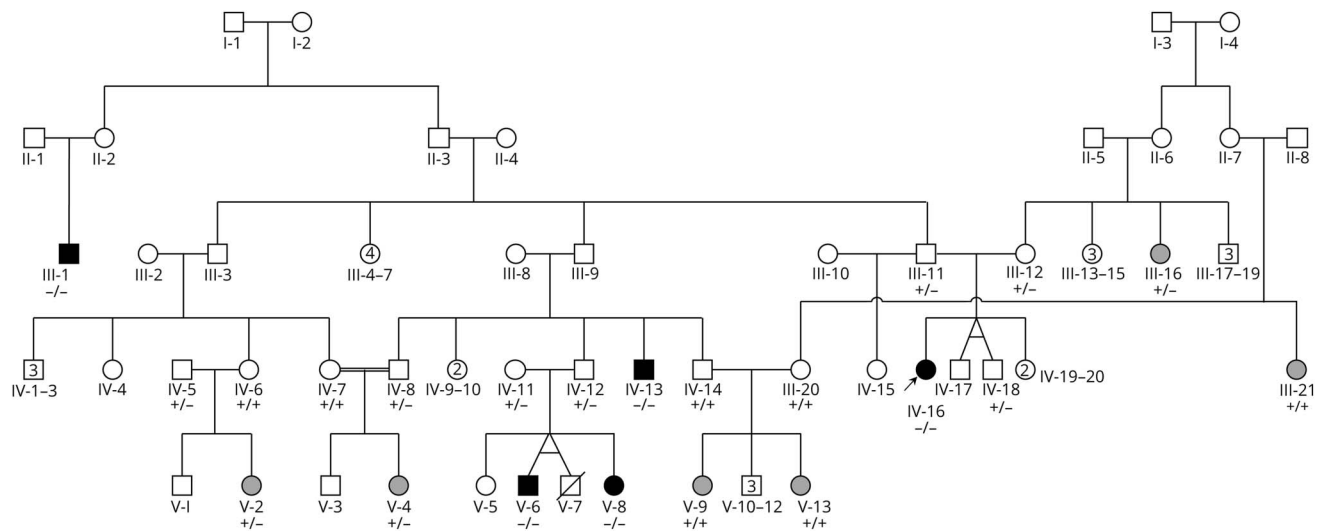
Standard protocol approvals, registrations and patient consents

Informed consent was obtained from all participants, and this study was approved by The Hospital for Sick Children Research Ethics Board, Toronto, Canada.

Results

Through analysis of rare CNVs detected from WGS data, a 1168-bp deletion was detected, spanning exons 8 and 9 of *VPS13A* (chr9:79827422-79828590); c.556_696del; p.(Thr186_Leu232del). The deletion was homozygous in both individuals sequenced and would likely result in an in-frame deletion of 47 amino acids. PCR amplification and Sanger sequencing confirmed the deletion and were used to test the pattern of segregation among all family members, where DNA was available (figure). Homozygosity mapping

Figure Pedigree of the family



“-” indicates the presence of *VPS13A* p.(Thr186_Leu232del). “+” indicates no deletion. Individuals without genotypes shown were not available for analysis. Black shapes indicate individuals affected with the primary disorder, and gray shapes indicate individuals affected with the second, separate phenotype. Individual V:7 died at the age of 10 years before the typical age at onset; thus, the affection status could not be determined. Numbers inside circles indicate more than 1 individual in the family. The index case is denoted by an arrow.

from the WGS data for participants III-1 and IV-16 showed that the deletion resides in an extended region of homozygosity in both individuals (chr9:78,311,259-98,376,367 in III-1 and chr9:79,451,734-97,016,027 in IV-16). Individuals IV: 13, V:8, and V:6 were found to be homozygous for the deletion. Family relationships were confirmed by the analysis of short tandem repeats. Analysis of single nucleotide variants and small insertion/deletions did not yield any pathogenic or likely pathogenic variants (all homozygous variants in coding regions identified in either individual are shown in table e-1, links.lww.com/NXG/A50). On peripheral blood smear, acanthocytes were detected in 3 of the 4 individuals with the primary condition (III:1, IV:13, and V:8) and in V:6, but not in the index case IV:16.

Discussion

The phenotype of the affected individuals is in keeping with the known CHAC phenotype. All 4 experienced choreoathetosis, seizures, and cognitive/psychiatric symptoms. Four members of the family were found to have acanthocytes on peripheral blood smear, supporting the diagnosis of CHAC. The molecular findings and hematology testing also confirmed the diagnosis of the youngest individual, V:6, presenting with the early stages of the condition. None of the 6 individuals with the second phenotype was homozygous for the deletion in *VPS13A* (3 did not carry the variant, and 3 were heterozygous), confirming that they likely have a second, distinct disorder.

There are 4 neuroacanthocytosis syndromes (CHAC, McLeod syndrome, Huntington disease-like 2, and pantothenate

kinase-associated neurodegeneration) with similar but distinct phenotypic features, and the clinical presentation of CHAC also overlaps with other disorders, presenting a diagnostic challenge.^{7,8} The presence of acanthocytes can be helpful to suggest a diagnosis of CHAC, but hematology results are inconsistent,^{7,8} as is the case in this family. With WGS, a precise diagnosis could be rapidly achieved without the requirement of any prior awareness of the disorder by the referring clinician. Achieving a correct diagnosis now allows accurate anticipation of the course of the disorder (particularly in the case of the youngest, mildly affected individual) and facilitates appropriate treatment.⁹ The diagnosis also prevents further unnecessary testing for possible nutritional or infectious etiologies and helps to remove any stigma associated with behaviors in the family.

The nature of the mutation in this family further demonstrates the benefit of using WGS compared with other nontargeted technologies. Such a small deletion would be too small to detect by microarray analysis and challenging to identify using exome sequencing. It may also not have been detected using a targeted gene or gene panel test, depending on the specific methodologies used. Small CNVs affecting *VPS13A*, such as the one identified in this family, have been found previously in cases with CHAC, although the deletion we describe had not been reported to date.¹⁰

Here, we present a large multigenerational family from Pakistan with chorea-acanthocytosis attributable to a 1168-bp, 2-exon deletion in *VPS13A*. This family showcases the potential for WGS as a first-tier diagnostic test in neurologic disorders.

Table 1 Clinical features of affected individuals

	III:1	IV:13	IV:16	V:8	V:6
Age at onset	35	30	27	26	
Present age					18
Choreoathetosis	+	+	+	+	
Orofacial dyskinesia	+	+	+	+	
Hyporeflexia	+				
Dysarthria	+	+	+	+	
Seizures	+	+	+	+	+
Tics	+	+	+	+	
Dystonia	+	+			
Parkinsonism	+	+			
Caudate atrophy	+	No MRI		No MRI	No MRI
Putamen atrophy	+	No MRI		No MRI	No MRI
Limb muscular atrophy	+				
Limb muscle weakness	+				
Dementia	+				
Personality changes	+	+	+	+	+
Mood changes	+	+	+	+	
Anxiety	+				+
Psychosis	+		One episode		
Aggressiveness			+		+
Dysphagia	+	+	+		
Droling	+	+			
Self-mutilation of the tongue	+	+	+		
Hematology	Acanthocytes	Acanthocytes		Acanthocytes	Acanthocytes

Author contributions

S. Walker: acquisition of data and analysis and interpretation of data. R. Dad and B. Thiruvahindrapuram: analysis and interpretation of data. I.M. Ullah: sample collection. A. Ahmad: acquisition of data and analysis and interpretation of data. M.J. Hassan, S.W. Scherer, and B.A. Minassian: critical revision of the manuscript and study supervision.

Acknowledgment

The authors thank the family for their participation in the study and The Centre for Applied Genomics for their analytical and technical support. This work was supported by The Centre for Applied Genomics, the University of Toronto McLaughlin Centre, Genome Canada/Ontario Genomics Institute, the Canadian Institutes of Health Research (CIHR), the Canadian Institute for Advanced Research,

and the Canada Foundation for Innovation. R.D. gratefully acknowledges her funding by the Higher Education Commission of Pakistan under the International Research Support Initiative Program (HEC-IRSIP). S.W.S. is funded by the GlaxoSmithKline-CIHR Chair in Genome Sciences at the University of Toronto and The Hospital for Sick Children. B.A.M holds the University of Toronto Michael Bahen Chair in Epilepsy Research and the University of Texas Southwestern Jimmy Elizabeth Westcott Distinguished Chair in Pediatric Neurology.

Study funding

This work was supported by The Centre for Applied Genomics, the University of Toronto McLaughlin Centre, Genome Canada/Ontario Genomics Institute, the Canadian Institutes of Health Research (CIHR), the Canadian Institute for Advanced Research, and the Canada Foundation for Innovation.

Disclosure

S. Walker, R. Dad, B. Thiruvahindrapuram, M.I. Ullah, A. Ahmad, and M.J. Hassan report no disclosures. S.W. Scherer holds the GlaxoSmithKline-CIHR Chair in Genome Sciences at the University of Toronto and The Hospital for Sick Children; is on the scientific advisory board of Deep Genomics; has served on the scientific advisory board of Population Diagnostics; has served on the editorial boards of *Genomic Medicine*, *Genes*, *Genomes*, *Genetics*, *the Journal of Personalized Medicine*, *the Open Genomics Journal*, *the Hugo Journal*, *Genome Medicine*, *the Journal of Neurodevelopmental Disorders*, *Autism Research*, *PathoGenetics*, *Comparative and Functional Genomics*, *BMC Medical Genomics*, and *Cytogenetics and Genome Research*; and has received research support from the Genome Canada/Ontario Genomics Institute, Canadian Institutes of Health Research, Canadian Institute for Advanced Research, McLaughlin Centre, Canada Foundation for Innovation, Government of Ontario, and NIH. B.A. Minassian holds patents for diagnostic testing of the following genes: *EPM2A*, *EPM2B*, *MECP2*, and *VMA21*; has received research support from the NIH; and has received license fee payments/royalty payments from patents for diagnostic testing of the following genes: *EPM2A*, *EPM2B*,

MECP2, and *VMA21*. Full disclosure form information provided by the authors is available with the full text of this article at Neurology.org/NG.

Received January 10, 2018. Accepted in final form April 5, 2018.

References

1. Rampoldi L, Dobson-Stone C, Rubio JP, et al. A conserved sorting-associated protein is mutant in chorea-acanthocytosis. *Nat Genet* 2001;28:119–120.
2. Lek M, Karczewski KJ, Minikel EV, et al. Analysis of protein-coding genetic variation in 60,706 humans. *Nature* 2016;536:285–291.
3. 1000 Genomes Project Consortium. A global reference for human genetic variation. *Nature* 2015;526:68–74.
4. Fu W, O'Connor TD, Jun G, et al. Analysis of 6,515 exomes reveals the recent origin of most human protein-coding variants. *Nature* 2013;493:216–220.
5. Trost B, Walker S, Wang Z, et al. A comprehensive workflow for read depth-based identification of copy-number variation from whole-genome sequence data. *Am J Hum Genet* 2018;102:142–155.
6. Yuen RKC, Merico D, Bookman M, et al. Whole genome sequencing resource identifies 18 new candidate genes for autism spectrum disorder. *Nat Neurosci* 2017;20:602–611.
7. Walterfang M, Evans A, Looi JCL, et al. The neuropsychiatry of neuroacanthocytosis syndromes. *Neurosci Biobehav Rev* 2011;35:1275–1283.
8. Walker RH. Untangling the thorns: advances in the neuroacanthocytosis syndromes. *J Mov Disord* 2015;8:41–54.
9. Benninger F, Afawi Z, Korczyn AD, et al. Seizures as presenting and prominent symptom in chorea-acanthocytosis with c.2343del VPS13A gene mutation. *Epilepsia* 2016;57:549–556.
10. Tomiyasu A, Nakamura M, Ichiba M, et al. Novel pathogenic mutations and copy number variations in the VPS13A gene in patients with chorea-acanthocytosis. *Am J Med Genet B Neuropsychiatr Genet* 2011;156B:620–631.

Neurology[®] Genetics

Chorea-acanthocytosis: Homozygous 1-kb deletion in VPS13A detected by whole-genome sequencing

Susan Walker, Rubina Dad, Bhooma Thiruvahindrapuram, et al.

Neurol Genet 2018;4;

DOI 10.1212/NXG.0000000000000242

This information is current as of May 18, 2018

Updated Information & Services	including high resolution figures, can be found at: http://ng.neurology.org/content/4/3/e242.full.html
References	This article cites 10 articles, 0 of which you can access for free at: http://ng.neurology.org/content/4/3/e242.full.html##ref-list-1
Subspecialty Collections	This article, along with others on similar topics, appears in the following collection(s): Chorea http://ng.neurology.org/cgi/collection/chorea
Permissions & Licensing	Information about reproducing this article in parts (figures, tables) or in its entirety can be found online at: http://ng.neurology.org/misc/about.xhtml#permissions
Reprints	Information about ordering reprints can be found online: http://ng.neurology.org/misc/addir.xhtml#reprintsus

Neurol Genet is an official journal of the American Academy of Neurology. Published since April 2015, it is an open-access, online-only, continuous publication journal. Copyright © 2018 The Author(s). Published by Wolters Kluwer Health, Inc. on behalf of the American Academy of Neurology. All rights reserved. Online ISSN: 2376-7839.

